Aster HOSPITALS & CLINICS
We'll Treat You Well

# HealthNews DIGEST

AUGUST 2025




4 Traditional and Robotic-Assisted Total Knee Arthroplasty (TKA)

7 Transnasal Endoscopic CSF Rhinorrhoea Repair

12 Acute Generalised Exanthematous Pustulosis (AGEP)

16 Haemodialysis

20 ACL and MPFL Reconstruction



31st Edition



## Dr. Sherbaz Bichu

CEO & Specialist Anaesthetist
Aster Hospitals & Clinics, UAE

On behalf of Aster's leadership, I am pleased to welcome you to the momentous 31st edition of our HealthNews Digest. From complex surgeries to rare diagnoses and path-breaking treatment approaches, your work continues to raise the bar for what is possible in healthcare. These successes are a testament to your unwavering dedication, resilience, and brilliance in navigating the most critical and complex cases with confidence and care.

In this spirit of medical excellence, I am proud to emphasise the continued success and growing impact of **COSMOS**, a heartfelt community initiative dedicated to conquering cancer through compassion, collaboration, and courage by facilitating the sharing of experiences, offering emotional support, and promoting community development to uplift others.

Together, we are transforming care and shaping healthier and more empowered communities. Let us carry this momentum forward with purpose, empathy, and a shared vision for a brighter, healthier future for all.



## Dr. Ramanathan V

**Medical Director**
**Aster Hospitals & Clinics, UAE**

As the Group Medical Director of Aster Hospitals and Clinics, I am delighted to welcome you to the 31st edition of HealthNews, a publication that continues to reflect the passion, precision, and purpose that define our medical fraternity for the exceptional work across specialities - from complex surgeries and life-saving interventions to clinical breakthroughs in diagnosis and treatment.

I would also like to highlight our most significant technological advancements: **Robotic Knee Joint Replacement System at Aster Hospital, Mankhool, Dubai.** With the integration of robotic systems in our orthopaedic unit, we can perform high-precision joint replacements and procedures with enhanced accuracy, smaller incisions, and quicker patient recovery times. This state-of-the-art equipment will revolutionise our orthopaedic operations, providing patients with reduced complications, better results and more advanced treatment alternatives.

These achievements reaffirm our collective mission-to lead with innovation, heal with compassion, and raise the standard of care for everyone who walks through our doors.

# A Case Study on Comparative Analysis of Traditional Total Knee Arthroplasty with Robotic-Assisted Total Knee Arthroplasty Performed on the Same Patient at Aster Hospital, Mankhool



**Dr. Ranjith Narayan**
Orthopaedics (Specialist)

## PRESENTATION

- 72-year-old female
- Medical history of type 2 Diabetes Mellitus, Hypertension and Hypothyroidism
- No family history of medical illness
- Admitted with:
  - Complaints of progressive pain in bilateral knees, more in the left than right, for one year
  - VAS Score: Left – 7/10; Right – 5/10
  - Affecting daily activities

## FINDINGS

### During Examination:

- Observation of waddling gait in the right and left knees
- Varus deformity present in both knees, more on the left than the right
- Tenderness in the medial joint line in the right and left knees
- Range of Motion: 0 to 120 in left knee; 5 to 120 in right knee
- No neurovascular deficits



Pre-operative X-ray Images

## DURING PROCEDURE

The patient underwent Staged Bilateral Total Knee Arthroplasty (Replacement) on a gap of 3 months, left side followed by right side. The left knee was done in traditional Measured Resection Technique (without Robotic Assistance), and the right knee was done under Robotic Assistance (ROSA):

### Total Knee Arthroplasty on Left Knee (Measured Resection Technique):

- The left knee was prepped and draped.
- A midline incision was made, and a medial parapatellar approach was taken.
- Medial side release was done.
- A distal femur cut of 9 mm was done in the 5-degree valgus jig, and a tibial cut of 10 mm from the lateral joint line was done.
- PCL was retained.
- A good balance was obtained in extension with a 10 mm spacer block.
- The AP sizing was done to size 5 femur, and 3-degree external rotation and APC cuts were done using an APC jig.
- After cutting, flexion balance was obtained in 10 mm blocks in 90 flexion.
- After preparation for implantation, cemented fixation was performed using a tibial tray size C with a 30 mm stem extension, as the tibial side bone was very osteoporotic. A femur size 5 CR implant was used, and the final balance was achieved with an 11 mm MC polyethylene liner.
- Wounds were closed in layers after the drain was placed.
- Good patellar tracking and full range of motion were obtained.

### Total Knee Arthroplasty on Right Knee (Robotic Assistance - ROSA):

- The right knee was prepped and draped.
- A midline incision was made, and a medial parapatellar approach was taken.
- Medial side release was done.
- Joint exposed and adequate soft tissue release was done.
- The ACL and osteophytes were excised.
- PCL was retained.
- Two pins were inserted on the tibia and femur to place Navi trackers.
- Using ROSA (Robotic Surgical Assistant), registration was completed and planned for femur size 6 with 1-degree external rotation to get a mechanical alignment and tibial cut to 9mm, balancing spaces in both flexion and extension.
- Femur cuts were done for size 6, followed by a tibial cut with a 7-degree posterior slope.
- Trial implantation was done. Good alignment and balance were ascertained using the Rosa.
- The femur was prepared for a narrow 6 mm implant, followed by tibia preparation to size C.
- The implants were implanted using cement.
- The patella tracking was good, and wounds were closed in layers after haemostasis was attained.

## FOLLOW-UP

### Post-op 6 months:

- VAS Score: Left Knee – 1/10; Right Knee – 0/10
- Walking unassisted with minimal waddling
- The deformity was fully corrected with a neutral alignment of the knees
- Range of movements: Left and Right Knees – 0 to 140 degrees
- Stable on Stress Test – mediolateral and antero-posterior

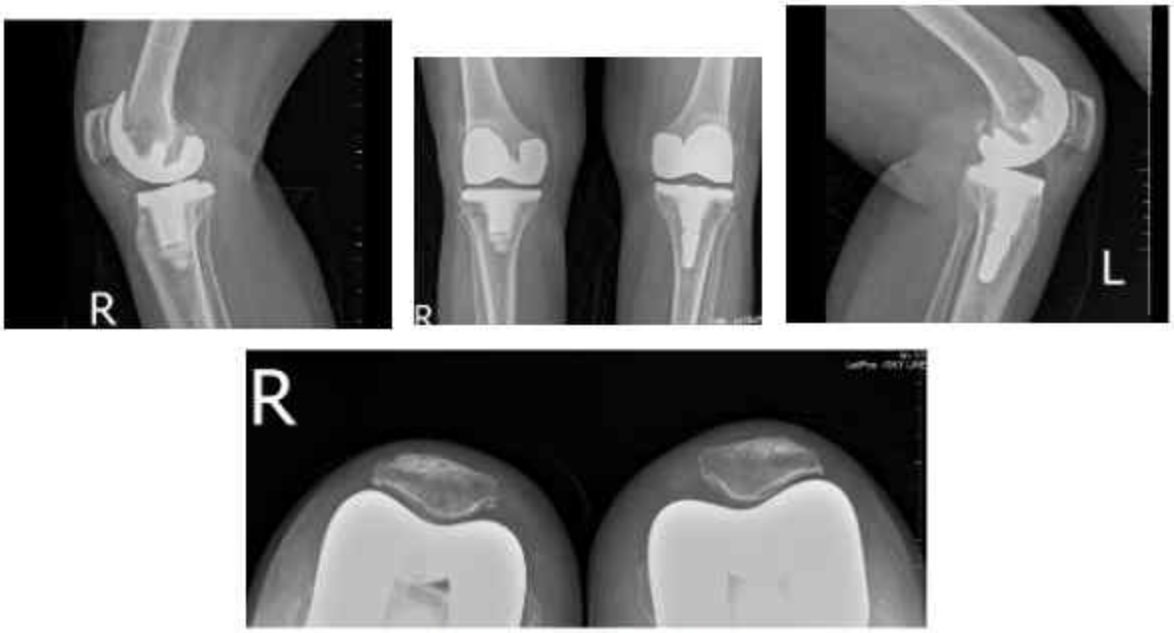


Post-op X-ray Images

## DISCUSSION

Robotic knee arthroplasty procedures have emerged as a new trend, garnering attention from orthopaedic surgeons globally. It has been hypothesised that robotics enhances the accuracy of prosthesis positioning and alignment restoration. The objective of this case study was to compare robotic total knee replacement with the conventional method.

In my personal experience, I found the advantages of knowing the desired mechanical axis through the surgery and adjusting the cuts as per the requirements.

Limited soft tissue releases, especially in the varus knee, reduce the chances of over-release.

Another advantage is the elimination of jigs for distal femoral and proximal tibia, especially in osteoporotic bones, avoiding errors in cuts due to pin loosening. Objective verification of the cuts in every step improves accuracy more than relying on subjective verification.

The femoral rotation can be changed to the desired value to improve the flexion space balance. Using robotic knee kinematic principles of replacement can be better executed.

## CONCLUSION

This case study indicates that robotic total knee replacements offer superior post-operative anatomical and mechanical alignment compared to conventional total knee replacements. Despite this, clinical and functional outcomes, as well as complication rates, were similar between the two. These findings should be considered in light of potential confounding factors. More randomised controlled trials with the latest robotic systems are needed to confirm superior functional and clinical outcomes from robotic-assisted surgeries.

## REFERENCES

1. Choi Y-J, RA HJ. Patient Satisfaction after Total Knee Arthroplasty. Knee Surg Relat Res. 2016 Feb 29;28(1):1–15. doi: 10.5792/ksrr.2016.28.1.1.
2. Kahlenberg CA, Nwachukwu BU, McLawhorn AS, et al. Patient Satisfaction After Total Knee Replacement: A Systematic Review. HSS J. 2018 Jul;14(2):192-201. doi: 10.1007/s11420-018-9614-8.
3. Clement ND, Calliess T, Christen B, Deehan DJ. An alternative technique of restricted kinematic alignment of the femur and gap balanced alignment of the tibia using computer aided navigation. Bone Joint Res. 2020;9(6):282-284. doi:10.1302/2046-3758.96.BJR-2020-0119.R1.

# Transnasal Endoscopic Approach in Cerebrospinal Fluid (CSF) Leak Repair: Technique and Outcomes



**Dr. Aneesa Ansar**
ENT (Specialist)
Aster Hospital, Al Qusais & Muhaisnah

## INTRODUCTION

Cerebrospinal fluid (CSF) rhinorrhoea is characterized by an abnormal communication between the subarachnoid space and the nasal cavity, typically resulting from a defect in the dura mater, skull base, and nasal mucosa (1). Because of the serious risks associated with conditions like meningitis, seizures, and hydrocephalus, it's crucial to quickly diagnose and treat cerebrospinal fluid (CSF) rhinorrhoea (1). Although CSF leaks can be traumatic or iatrogenic, spontaneous leaks are increasingly recognized, particularly among middle-aged obese women, and are often associated with idiopathic intracranial hypertension (2). Clinically, patients may present with unilateral, clear and watery nasal discharge, which is exacerbated by bending or Valsalva maneuver, along with symptoms like headache, salty or metallic taste in the mouth, blurred vision and confusion, anosmia, or recurrent meningitis (2).

Various techniques have been described for the surgical repair of CSF leaks at the anterior skull base (3). These include the transcranial approach via bifrontal craniotomy, extracranial access through external ethmoidectomy or frontal sinusotomy, and the transnasal route using either microscopic or endoscopic visualization (3). Among these, the transnasal endoscopic approach has become the preferred technique, owing to its superior success rates, reduced morbidity, and more reliable defect closure (3).

This article outlines the transnasal endoscopic technique for CSF leak repair, detailing each step of the procedure, presenting clinical outcomes, and emphasizing its key advantages.

## STEPWISE APPROACH TO TRANSNASAL ENDOSCOPIC REPAIR OF CSF LEAKS

Transnasal endoscopic repair has revolutionized the management of anterior skull base CSF leaks by offering direct visualization and minimally invasive access to the defect site (1). This approach allows precise identification and tailored reconstruction of the skull base defect, optimizing surgical outcomes while preserving sinonasal function (1).

The repair process involves several critical steps (4):

### Step 1: Preoperative localization of the leak site

- High-resolution computed tomography and magnetic resonance cisternography are utilized to delineate the defect's size and anatomical location, facilitating surgical planning and approach selection (5).
- To enhance access and visualization of the skull base and leak site, a rigid nasal endoscope is introduced transnasally, often accompanied by partial middle turbinate resection or lateralization (3).
- When direct visualization of the CSF leak is uncertain, intrathecal fluorescein administration is administered intraoperatively, significantly improving localization accuracy through fluorescence detection (1).

### Step 2: Defect preparation

- The surrounding mucosa is carefully elevated and stripped from the bony margins. This step is essential to create a viable graft bed and remove any bony irregularities that may hinder graft adherence and sealing (3).

### Step 3: Graft selection and placement

a. For small defects (<1 $cm^2$):

- An overlay graft using autologous tissue (e.g., mucoperiosteum or fascia) is typically sufficient (3).

b. For larger or high-flow defects:

- A multilayer closure is employed using underlay, interlay, and overlay grafts.
- Materials such as fascia lata, abdominal fat, or acellular dermal matrices are used to ensure a robust and watertight seal (3).

c. In cases of elevated intracranial pressure or large defects:

- The gasket-seal technique using a rigid buttress combined with grafts may be applied to provide structural support and prevent recurrence (3).

### Step 4: Flap coverage

- Hemostasis is achieved, and the repair site is inspected for any residual CSF leakage.
- Absorbable nasal packing materials such as gelatin foam or Merocel are applied to stabilize the graft and control bleeding during the initial postoperative period (6).

### Step 5: Postoperative management

- Includes head elevation and activity modifications to minimize intracranial pressure fluctuations, alongside regular endoscopic follow-up to ensure successful healing and early detection of complications (3).

## EFFICACY OF THE TRANSNASAL ENDOSCOPIC APPROACH FOR CSF LEAK REPAIR

The transnasal endoscopic approach has emerged as the preferred technique for repairing anterior skull base CSF leaks (3). Its widespread adoption is largely due to a combination of high success rates, low morbidity, and the preservation of sinonasal function, particularly when modern multilayered reconstruction methods are used (3).

Clinical outcomes consistently support the efficacy of this approach. In a prospective cohort of 21 patients with CSF rhinorrhea, the primary closure success rate reached 90.5% following the initial transnasal endoscopic repair, and complete closure was achieved in 100% of cases after a second procedure when necessary (3). These findings align closely with broader data, including a meta-analysis that reported primary repair success rates around 90%, with secondary interventions bringing success rates up to 97% (2). For spontaneous CSF rhinorrhoea, endoscopic repair has shown a 96% success rate, with recurrence occurring in just 4% of cases (2).

Anatomical site plays a significant role in surgical outcomes. The highest closure rates were observed in defects involving the sphenoid sinus and fovea ethmoidalis, especially when larger than 1 $cm^2$ and treated with multilayer closure and graft-flap combinations as presented in Figure 1 (3). Conversely, defects at the lateral lamella demonstrated the lowest closure rates, achieving only 50% success (3).

**Success Rates of Transnasal Endoscopic CSF Leak Repair by Clinical Parameters (3)**

| Variable | Subgroup | Success Rate (%) |
|---|---|---|
| Anatomical Site of Leak | Sphenoid Leak | 100 |
| | Fovea Ethmoidalis | 100 |
| | Cribriform Plate | 83.3 |
| | Lateral Lamella | 50 |
| Defect Size | <1 $cm^2$ | 87.5 |
| | >1 $cm^2$ | 100 |
| Surgical Technique | Multilayer Technique | 100 |
| | Gasket Seal | 100 |
| | Overlay | 71.4 |
| Material Used | Graft + Flap Material | 100 |
| | Graft Only | 83.3 |
| | Flap Only | 75 |

Figure 1: Success Rates of Transnasal Endoscopic CSF Leak Repair by Clinical Parameters (3)

In addition, multilayer and combined reconstruction techniques consistently achieved 100% closure (3).

## SURGICAL AND FUNCTIONAL OUTCOMES OF TRANSNASAL ENDOSCOPIC TECHNIQUE

The transnasal endoscopic repair is associated with a favorable complication profile. Overall postoperative morbidity remains low, and sinonasal function is generally well preserved (2). Mild hyposmia has occasionally been reported, especially in cases involving the harvesting of a nasoseptal flap, though these sensory changes typically do not result in long-term impairment (2). Serious complications like meningitis and permanent anosmia have been reported in approximately 20.8% of cases, with anosmia occurring more often when the cribriform plate is involved in the repair (2). Notably, cases of postoperative meningitis have been effectively managed with antibiotics, highlighting the importance of prompt and effective postoperative care (2).

Functional outcomes further support the value of this technique. Postoperative assessments showed consistent improvement in sinonasal quality-of-life scores (3). The mean SNOT-22 score dropped from 17.74 preoperatively to 5.55 at six months following surgery, indicating a marked improvement in patient-reported symptoms (3). Radiological follow-up confirmed anatomical stability, with no evidence of new opacification or structural deformity. Additionally, scores on the POSE and Lund-Mackay scales remained stable postoperatively, reinforcing the reliability of this approach (3).

Figure 2 illustrates the longitudinal changes in sinonasal and olfactory function scores measured preoperatively and 6 months postoperatively, highlighting the progressive recovery and sustained improvement after the procedure (3).

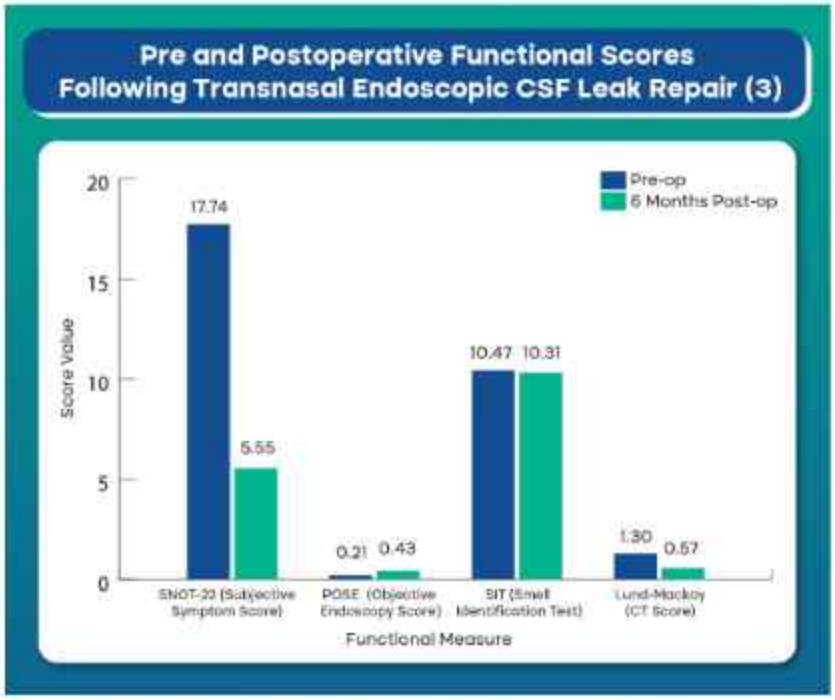


**Figure 2: Pre and Postoperative Functional Scores After Transnasal Endoscopic CSF Leak Repair (3)**

(Abbreviations - SNOT-22: Sino-nasal Outcome Test – 22 item version; POSE: Perioperative Sinus Endoscopy; SIT: Smell Identification Test; CT: computed tomography)

The postoperative improvements in symptom scores, endoscopic findings, olfaction, and imaging depend on factors such as defect size, repair technique, and materials used. Although a temporary worsening may occur early due to the healing process, preserving olfactory function and minimizing mucosal trauma are essential for achieving optimal sinonasal outcomes (3).

In the long term, the transnasal endoscopic method offers durable closure with minimal recurrence and limited functional compromise, solidifying its role as the standard of care for both primary and revision CSF leak repairs (2,3).

## Key Highlights

- Transnasal endoscopic CSF leak repair is performed using a stepwise approach involving mucosal elevation, skull base drilling, and multilayer closure techniques such as overlay, multilayer, or gasket seal using grafts and vascularized flaps (3).
- The technique achieves up to 100% closure with multilayer and flap techniques, particularly for large or high-flow leaks (3).
- This minimally invasive method results in low morbidity, preserved sinonasal function, and significant improvements in patient-reported outcomes , with minor, manageable complications such as transient anosmia or meningitis (3).

# REFERENCES


1. Mughal Z, Martinez-Devesa P, Boukas A, Jeyaretna S, Qureishi A. Contemporary Management of Cerebrospinal Fluid Rhinorrhoea: A Review of the Literature. J Clin Med [Internet]. 2025 Feb 4 [cited 2025 May 20];14(3):995. Available from: https://www.mdpi.com/2077-0383/14/3/995
2. Rasras S, Nikakhlagh S, Safari H, Cheraghian Z, Noroozi S. Effectiveness of endoscopic surgery for treating spontaneous cerebro spinal fluid rhinorrhea. Interdiscip Neurosurg [Internet]. 2025 Jun [cited 2025 May 20];40:102033. Available from: https://linkinghub.elsevier.com/retrieve/pii/S2214751925000453
3. Baban MI, Shareef DJ, Hadi SJ, Shawkat A, Castelnuovo P. Outcomes of transnasal endoscopic repair of cerebrospinal fluid leaks: a prospective cohort study. Egypt J Otolaryngol [Internet]. 2022 Dec [cited 2025 May 20];38(1):61. Available from: https://ejo.springeropen.com/articles/10.1186/s43163-022-00243-9
4. Bubshait RF, Moumen AA. The Endonasal Endoscopic Management of Cerebrospinal Fluid Rhinorrhea. Cureus [Internet]. 2021 Feb 20 [cited 2025 May 20]; Available from: https://www.cureus.com/articles/39071-the-endonasal-endoscopic-management-of-cerebrospinal-fluid-rhinorrhea
5. Xie M, Zhou K, Kachra S, McHugh T, Sommer DD. Diagnosis and Localization of Cerebrospinal Fluid Rhinorrhea: A Systematic Review. Am J Rhinol Allergy [Internet]. 2022 May [cited 2025 May 20];36(3):397–406. Available from: http://journals.sagepub.com/doi/10.1177/19458924211060918
6. Lee IH, Kim DH, Park JS, Jeun SS, Hong YK, Kim SW. Cerebrospinal fluid leakage repair of various grades developing during endoscopic transnasal transsphenoidal surgery. Psaltis AJ, editor. PLOS ONE [Internet]. 2021 Mar 26 [cited 2025 May 20];16(3):e0248229. Available from: https://dx.plos.org/10.1371/journal.pone.0248229

# Severe Cutaneous Adverse Reaction (SCAR) triggered by Medications resulting in Acute Generalised Exanthematous Pustulosis (AGEP) treated effectively at Aster Cedars Hospital and Clinic, Jebel Ali



**Dr. Rakesh Kumar Mishra**
Dermatology (Specialist)

## PRESENTATION

- 39-year-old male without any known medical condition
- History of fever with itchy skin & extensive red rash involving face and trunk, since last about 10 days, allegedly started after consuming Oral Allopurinol tablets for high uric acid. The symptoms subsided after the medicine was stopped and recurred after it was restarted.
- No significant personal or family history of drug allergy

## EXAMINATION

The patient was admitted to the hospital with initial findings of:

- Fever (100.0°F)
- Numerous non-follicular pruritic, pustular and papulopustular lesions of various sizes (<5mm) on an erythematous base, present all over the face, neck, chest, abdomen, back and both upper & lower limbs. Palms and soles were relatively spared
- Minimal mucosal/oral lesions with no genital/ocular involvement
- No skin peeling or blister seen
- Nikolsky sign negative
- The patient was stable, fully conscious, oriented and was feeding orally, with normal bowel and bladder function
- No other systemic complaints
- No pain in the abdomen or shortness of breath



Pre-treatment Pictures

## INVESTIGATIONS

- CBC: 22700 (N:55, L:37, E:15)
- CRP: 57.4
- LFT/KFT: Normal limits

## DIFFERENTIAL DIAGNOSIS

### Clinical Diagnosis of:

- Acute Generalised Exanthematous Pustulosis (AGEP)

### Other differentials considered were:

- Drug Rash Eosinophilia and Systemic Symptoms (DRESS)
- Pustular Psoriasis
- Eosinophilic Pustular Folliculitis (EPF), also known as Ofuji disease
- Subcorneal Pustular Dermatosis (SCPD)

Based on clinical findings, history of drug intake and recurrence on subsequent exposure and using the AGEP score (proposed by the EuroSCAR group), a diagnosis of AGEP was made (the patient refused skin biopsy on some religious grounds).

## MANAGEMENT AND CONCLUSION

The patient was managed as a case of Drug-induced AGEP with Systemic steroids, antihistamines, topical emollients and other conservative measures. After one week of treatment, the skin lesions began to dry, and the erythema reduced. After two weeks, skin drying and peeling began, accompanied by a reduction in itching. By the third week, the patient was very comfortable, with only a slight amount of itching and erythema remaining, and the skin had regained its normal texture. However, topical emollients and antihistamines were continued for another two weeks.



Post-treatment Pictures

## PROGNOSIS

AGEP has an excellent prognosis when recognised in time. Management focuses on timely identifying incriminating drugs or any infectious aetiology and stopping the drug with close monitoring and supportive measures. Diagnosis is primarily clinical, with a temporal association of drug history, and occasionally, a histological diagnosis may be needed to confirm the diagnosis.

## DISCUSSION

AGEP, first described in 1968 and later defined in 1980, remains a subject of ongoing study. AGEP is estimated to occur in one to five people per million per year [1,2]. AGEP has been reported more frequently in women, with a mean age of 56 years [3]. AGEP has been associated with increased body mass index; the mechanism may be related to upregulated proinflammatory cytokines secondary to obesity [4,5]. Notably, certain drugs carry a higher epidemiological risk than others; these include pristinamycin, ampicillin, amoxicillin, quinolones, allopurinol, hydroxychloroquine, sulfonamides, terbinafine, and diltiazem [6,7].

AGEP typically presents within 24–48 hours of ingestion of the offending drug, with a median time of 24 hours for antibiotics in particular. However, some drugs have been shown to have a lag time of up to 10–22 days; therefore, this is not a defining feature [8,9]. Prodromal signs include fever (temperature>38°C) and generalised malaise, accompanied by leukocytosis, particularly neutrophilia, and eosinophilia in up to 30% of patients [8]. This is accompanied by an edematous erythema and a pruritic pustular eruption that favours the trunk and intertriginous areas, often sparing the mucous membranes, followed by desquamation of the affected areas. The pustules are sterile, non-follicular, and numerous. Mucosal involvement occurs in approximately 20% of cases [10]. When mucosal involvement occurs, the rash is usually limited to a single site, such as the lips or buccal mucosa.

Systemic involvement is considered to be any organ dysfunction that occurs with cutaneous features that cannot be attributed to any other cause or disease. Studies have shown that 17–20% of AGEP cases have internal organ involvement, most often hepatic, renal, or pulmonary disease [8,11,12].

## REFERENCES


1. Oh DAQ, Yeo YW, Choo KJL, Pang SM, Oh CC, Lee HY. Acute generalized exanthematous pustulosis: Epidemiology, clinical course, and treatment outcomes of patients treated in an Asian academic medical center. JAAD Int. 2021;3:1–6. doi: 10.1016/j.jdin.2020.12.004.
2. Mofarrah R, Mofarrah R, Oshriehye M, Ghobadi Aski S, Nazemi N, Nooshiravanpoor P. The necessity of patch testing in determining the causative drug of AGEP. J Cosmet Dermatol. 2021;20(7):2156–2159. doi: 10.1111/jocd.13841.
3. Feldmeyer L, Heidemeyer K, Yawalkar N. Acute Generalized Exanthematous Pustulosis: Pathogenesis, Genetic Background, Clinical Variants and Therapy. Int J Mol Sci. 2016;17(8):1214. doi: 10.3390/ijms17081214.
4. Gallardo MA, Mallela T, Gilkey T, Himed S, Walker TD, Nusbaum KB, et al. Demographic and laboratory differences seen between acute generalized exanthematous pustulosis and drug reaction with eosinophilia and systemic symptoms: a cross-sectional analysis. J Am Acad Dermatol. 2022.
5. Nusbaum KB, Walker TD, Himed S, Trinidad JC, Spaccarelli N, Chung C, et al. Patient Care Outcomes in Hospitalized Patients with Acute Generalized Exanthematous Pustulosis: A Cross-Sectional Database Study. Am J Clin Dermatol. 2023;24(2):299–304. doi: 10.1007/s40257-022-00737-5.
6. Sidoroff A, Dunant A, Viboud C, Halevy S, Bavinck JNB, Naldi L, et al. Risk factors for acute generalized exanthematous pustulosis (AGEP)-results of a multinational case-control study (EuroSCAR). Br J Dermatol. 2007;157(5):989–996. doi: 10.1111/j.1365-2133.2007.08156.x.
7. Meier-Schiesser B, Feldmeyer L, Jankovic D, Mellett M, Satoh TK, Yerly D, et al. Culprit Drugs Induce Specific IL-36 Overexpression in Acute Generalized Exanthematous Pustulosis. J Invest Dermatol. 2019;139(4):848–858. doi: 10.1016/j.jid.2018.10.023.
8. Szatkowski J, Schwartz RA. Acute generalized exanthematous pustulosis (AGEP): a review and update. J Am Acad Dermatol. 2015;73(5):843–848. doi: 10.1016/j.jaad.2015.07.017.
9. Shear N, Dodiuk-Gad RP. Advances in Diagnosis and Management of Cutaneous Adverse Drug Reactions Current and Future Trends: Current and Future Trends. ResearchGate, 2019. doi: 10.1007/978-981-13-1489-6.
10. Aiempanakit K, Apinantriyo B. Clindamycin-induced acute generalized exanthematous pustulosis: a case report. Medicine (Baltimore) 2020;99(21):e20389. doi: 10.1097/MD.0000000000020389.
11. Hotz C, Valeyrie-Allanore L, Haddad C, Bouvresse S, Ortonne N, Duong TA, et al. Systemic involvement of acute generalized exanthematous pustulosis: a retrospective study on 58 patients. Br J Dermatol. 2013;169(6):1223–1232. doi: 10.1111/bjd.12502.

# Improving Haemodialysis Outcomes: Strategies for Patient-Centred ESKD Care



**Dr. John Cherian Varghese**
Nephrology (Specialist)
Aster Hospital, Mankhool & Al Qusais

## INTRODUCTION

The health burden of end-stage kidney disease (ESKD) is increasing globally, primarily driven by ageing, diabetes, and hypertension (1). In the United States, EKSD cases jumped 118.7% from 2000 to 2019. Diabetes had a link to half of these new cases, while hypertension had a connection to almost a third (2). Estimates suggest that by 2030, more than 5.4 million people worldwide will require kidney replacement therapy (KRT) (1).

KRT includes haemodialysis (HD), peritoneal dialysis, and kidney transplantation, with HD being the most common therapy, especially where transplant infrastructure is lacking (3,4). HD involves extracorporeal blood circulation for solute and fluid removal, supported by vascular access, dialysate preparation, and the use of agents such as heparin, intravenous iron, and erythropoiesis-stimulating agents (5). More than two million people worldwide received dialysis treatment by 2020, with over 550,000 cases in the U.S. only (6). Treatment typically occurs three times per week, with sessions lasting about four hours (1).

While haemodialysis is a technically complex process, it is generally considered safe (5). Advances in dialysis technology, water purification systems, and stringent treatment protocols have significantly minimised the risk of serious complications (5). Extended home HD is associated with a 40% lower risk of all-cause mortality compared to in-centre HD, and offers improved phosphate and blood pressure control, better nutritional and inflammatory profiles, and reduced hospitalisations and medication needs (3). The EKSD Life-Plan approach promotes a continuum-of-care model for chronic kidney disease (CKD) to ESKD, aligning dialysis modalities and access strategies with patient goals and preferences (4).

This article outlines a structured clinical framework for HD care, focused on patient optimisation, complication management, and strategies to support individualised, patient-centred outcomes.

## OPTIMISING THE PATIENT BEFORE INITIATING HAEMODIALYSIS

Patients with CKD preparing to start HD, whether predialysis, transitioning from another KRT modality (such as peritoneal dialysis or a failing kidney transplant), or already on dialysis with a failing access, require timely planning for new vascular access (4). Patients with non-dialysis chronic kidney disease who show a progressive decline in renal function should be referred for vascular access planning once their estimated glomerular filtration rate (eGFR) falls within the 15–20 mL/min/1.73 $m^2$ range. (4).

Given that hypertension and diabetes are leading causes of CKD and ESKD, early management of risk factors is crucial. Evidence shows that controlling blood pressure and glucose can delay progression to ESKD, particularly in patients with diabetes (7).

Figure 1 presents a structured clinical checklist to guide the pre-HD optimisation process.

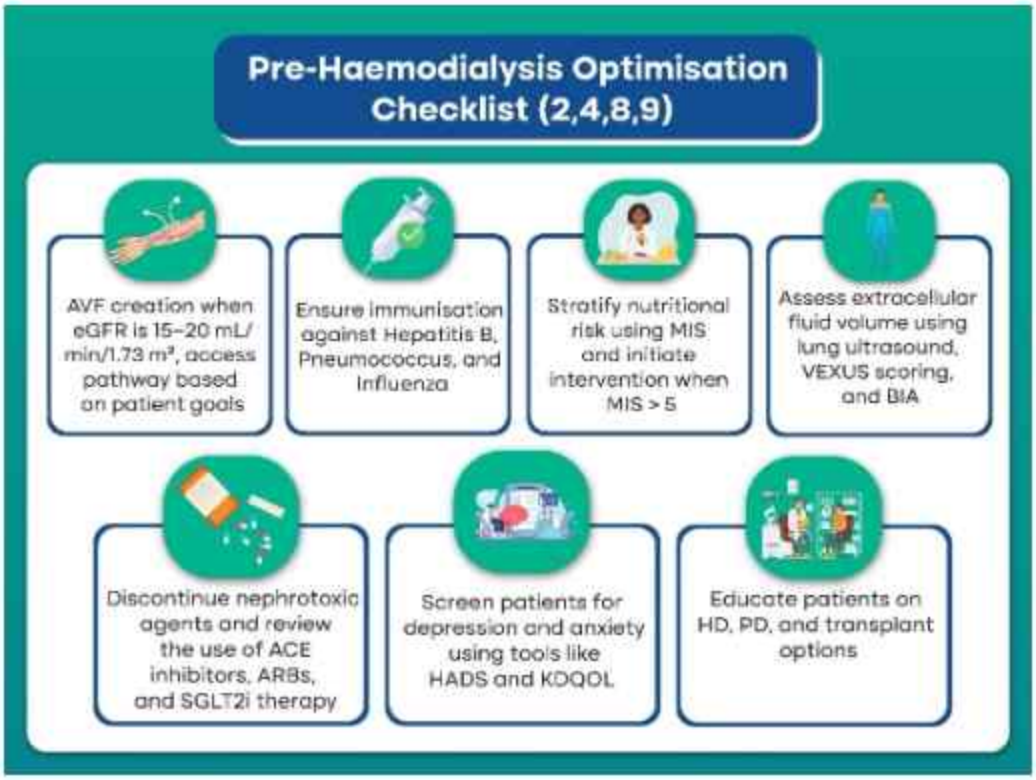


**Figure 1. Clinical prerequisites for safe and effective initiation of HD (2,4,8,9)**

(Abbreviations – AVF: arteriovenous fistula; eGFR: estimated glomerular filtration rate; MIS: malnutrition–inflammation score; NR: nutritional risk; KDQOL: Kidney Disease Quality of Life; VEXUS: venous excess ultrasound score; BIA: bioimpedance analysis; ACEi: angiotensin-converting enzyme inhibitor; ARB: angiotensin receptor blocker; SGLT2i: sodium–glucose co-transporter-2 inhibitor; HADS: Hospital Anxiety and Depression Scale; HD: haemodialysis; PD: peritoneal dialysis; CKD: chronic kidney disease)

Beyond the clinical checklist, the ESKD Life-Plan framework highlights the need for broader, system-level strategies to support timely and effective HD initiation (4). These strategies involve collaborative planning that includes the patient's goals, clinical condition, and treatment preferences to optimise access and readiness for dialysis (4). Key strategic considerations include:

- **Multidisciplinary care:** Structured intake, patient education, coordinated referrals, and individualised timelines improve arteriovenous access placement and clinical outcomes (4).
- **Individualised modality planning:** While HD is the most common modality worldwide, selection should consider clinical, social, and geographic factors to ensure equitable access and patient-centred care (1).
- **Continuum of care:** The Life-Plan approach ensures ongoing alignment between modality selection and access strategy, allowing for flexibility as clinical circumstances evolve (4).

## MANAGING COMPLICATIONS AND ENHANCING PATIENT-CENTRED OUTCOMES

While HD alleviates ESKD symptoms and improves the quality of life (QoL), long-term therapy is associated with multiple complications that impact patient outcomes (7). Understanding and addressing these proactively is critical to optimise care (4).

### Common complications include:

- **Cardiovascular disease, infections, and metabolic disturbances** – the leading causes of morbidity and mortality (7).
- **Vascular access site infections**, followed by pneumonia and soft tissue infections (7).

- **Malnutrition,** affecting 62% of patients, is strongly associated with poorer physical and mental health, especially when the malnutrition-inflammation score (MIS) exceeds 5 (8).
- **Mental health issues** – depression (26.5%) and anxiety (43.4%) are prevalent, and are linked to poor adherence and reduced QoL (10).

Figure 2 summarises systemic and access-related complications associated with HD.

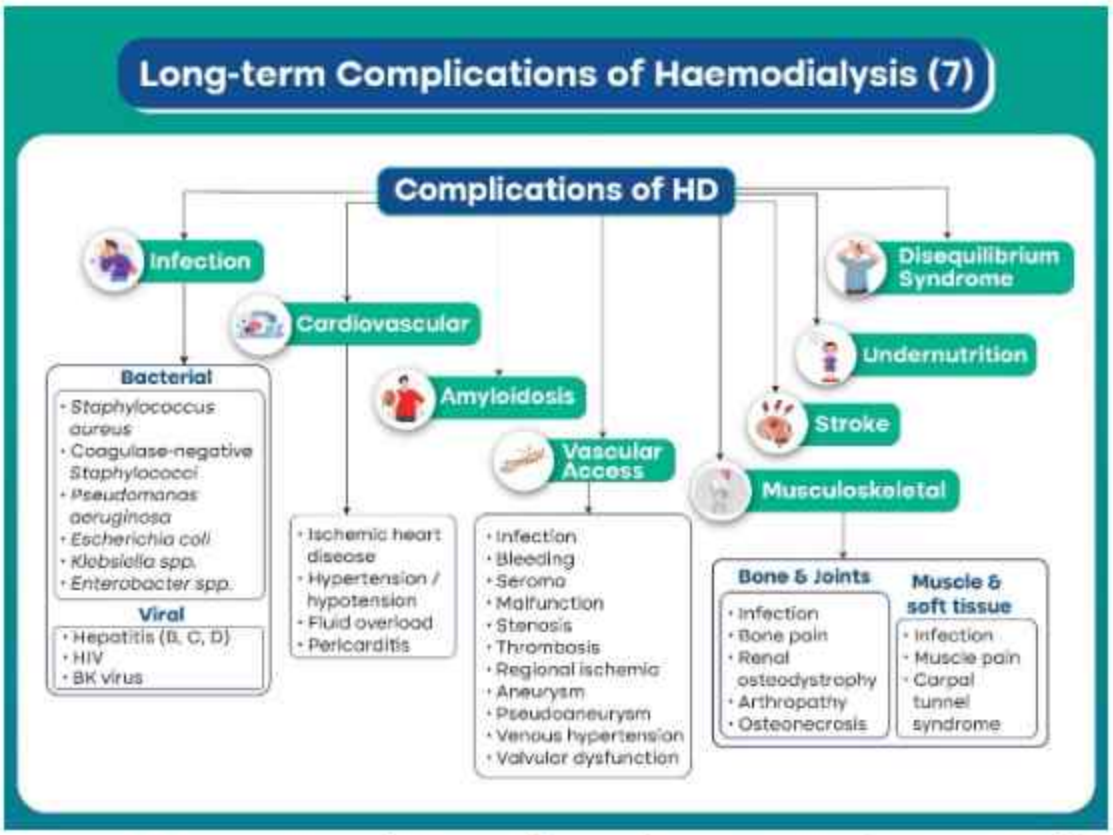


**Figure 2. Common complications observed in patients undergoing HD (7)**

(Abbreviations – IHD: ischaemic heart disease; HD: haemodialysis; HIV: human immunodeficiency virus; BK virus: Belden King Virus)

To mitigate these complications and enhance long-term outcomes, current evidence supports the following targeted interventions:

- **Infection control:** The Kidney Disease Outcomes Quality Initiative (KDOQI) recommends the establishment of infection surveillance teams to monitor and prevent vascular access infections, one of the most frequent complications in HD care (4).
- **Nutritional support:** Interventions based on the MIS score can lead to improvements in both physical and mental aspects of the Kidney Disease Quality of Life Short Form (KDQOL-SF) (10).
- **Psychosocial interventions:** Behavioural therapies, exercise training, and counselling can alleviate depression, improving emotional wellbeing and treatment adherence (10).
- **eHealth innovations:** Digital tools such as telephonic counselling and digital cognitive behavioural therapy (CBT) are effective in reducing depression and anxiety, while promoting patient engagement (11).
- **Dialysis regimen individualisation:** Extended home HD is associated with 40% lower all-cause mortality, improved phosphate and BP control, better nutritional status, and fewer hospitalisations compared to in-centre HD (3).

## Key Highlights

- The global burden of ESKD is rising, primarily driven by diabetes, hypertension, and an ageing population, with over 5.4 million people projected to require KRT by 2030 (1,2).
- Comprehensive pre-dialysis optimisation, including vascular access planning, vaccination, nutritional and fluid assessment, and mental health screening, is critical for ensuring timely and effective dialysis initiation (4,8,10).
- Long-term success in HD care requires proactive complication management of cardiovascular risk, infections, malnutrition, and psychological health (3,7,11).
- Emerging innovations such as eHealth innovations and personalised dialysis strategies (including extended home HD and digital CBT) are emerging as effective tools to reduce complications and improve patient-centred outcomes (11).

## REFERENCES


1. Thurlow JS, Joshi M, Yan G, Norris KC, Agodoa LY, Yuan CM, et al. Global Epidemiology of End-Stage Kidney Disease and Disparities in Kidney Replacement Therapy. Am J Nephrol. 2021;52(2):98–107.
2. Ríos Burrows N, Koyama A, Pavkov ME. Reported cases of end-stage kidney disease—United States, 2000–2019. American Journal of Transplantation. 2022 May;22(5):1483–6.
3. Ok E, Demirci C, Asci G, Yuksel K, Kircelli F, Koc SK, et al. Patient Survival With Extended Home Hemodialysis Compared to In-Center Conventional Hemodialysis. Kidney International Reports. 2023 Dec;8(12):2603–15.
4. Lok CE, Huber TS, Lee T, Shenoy S, Yevzlin AS, Abreo K, et al. KDOQI Clinical Practice Guideline for Vascular Access: 2019 Update. American Journal of Kidney Diseases. 2020 Apr;75(4):S1–164.
5. Greenberg KI, Choi MJ. Hemodialysis Emergencies: Core Curriculum 2021. American Journal of Kidney Diseases. 2021 May;77(5):796–809.
6. Flythe JE. Dialysis—Past, Present, and Future: A Kidney360 Perspectives Series. Kidney360. 2023 May;4(5):567–8.
7. Habas E, Habas A, Elgamal M, Shraim B, Moursi M, Ibrahim A, et al. Common complications of hemodialysis: A clinical review. Ibnosina Journal of Medicine and Biomedical Sciences. 2021 Dec;13(04):161–72.
8. Visiedo L, Rey L, Rivas F, López F, Tortajada B, Giménez R, et al. The impact of nutritional status on health-related quality of life in hemodialysis patients. Sci Rep. 2022 Feb 22;12(1):3029.
9. Sam R, Rankin L, Ulasi I, Frantzen L, Nitsch D, Henner D, et al. Vaccination for Patients Receiving Dialysis. Kidney Medicine. 2024 Mar;6(3):100775.
10. Yang H, Qi L, Pei D. Effect of psychosocial interventions for depression in adults with chronic kidney disease: a systematic review and meta-analysis. BMC Nephrol. 2024 Jan 10;25(1):17.
11. Zhou XH, Chen H, Yang W, Wang L, Chen L, Zhu Y, et al. Efficacy of eHealth Interventions for Hemodialysis Patients: Systematic Review and Meta-Analysis. J Med Internet Res. 2025 Mar 26;27:e67246.

# Successful Anterior Cruciate Ligament (ACL) and Medial Patellofemoral Ligament (MPFL) Reconstruction done on Left Knee for Recurrent Dislocation of Patella and Anterior Cruciate Ligament Tear at Aster Hospital, Muhaisnah



**Dr. Masoodh Basha**
Orthopaedics (Specialist)

## PRESENTATION

A 25 year old male presented to us with:

- History of fall while playing recreational football 2 months ago
- Left knee pain, swelling and instability for 2 months, inability to walk properly and a feeling of the kneecap (patella) and knee giving way while walking or running
- Recurrent patellar subluxation many times over the last 7 years but patient couldn't recall dislocation of the patella

## FINDINGS

### Left knee examination:

- Ligamentous laxity was seen
- No effusion
- PFJ no creptitus/tenderness laterally
- Patella - Medial patellofemoral ligament (MPFL) was lax - lateral translation was found to be excessive - 3 quadrants in full extension
- Apprehension sign +
- J sign +
- Stable at 45-degree flexion
- No meniscus tenderness
- Mc Murray +
- No varus valgus instability
- Mild muscle wasting
- Lachman's +
- Ant drawer grade 2 +
- Pivot shift grade 1 +
- ROM full

Clinically, the patient had an ACL tear, causing anterior laxity of the tibia and an MPFL tear, causing lateral laxity of the patella.

### X-ray showed:

- Left lateral patellar tilt
- Mild patella alta
- Osgood-Schlatter disease

### MRI showed:

- Full-thickness tear of the upper 1/3rd of the ACL
- Grade 2 signal intensity changes in both menisci
- MPFL was thin and stretched out
- Patella alta – modified Insall Salvati ratio of 1.88 and TT TG distance of 20.2 mm
- Osgood-Schlatter disease

**Pre-op X-ray Images**



Left patella subluxed laterally



Osgood-Schlatter disease

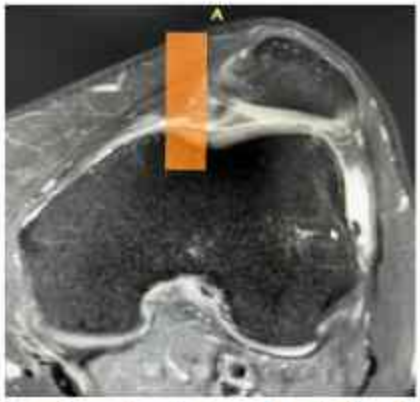

MRI showing lateral patellar tilt



Lateral tilt of left patella

## PLANNING

The condition and options were discussed with the patient. His two main problems were an ACL tear, for which ACL reconstruction was required, and patella instability, for which either an MPFL reconstruction or tibial tubercle osteotomy was required. The options were to do MPFL or ACL reconstruction as two separate surgeries or both together in the same sitting. The other surgery was a tibial tubercle osteotomy for the patella subluxation with ACL reconstruction.

A combined surgery would shorten the recovery period, rather than having two surgeries and physiotherapy sessions spaced over a few months.

In view of the borderline patella alta and Osgood-Schlatter disease, it was decided to proceed with MPFL and ACL reconstruction in same sitting and have tibial tubercle osteotomy as salvage option in case MPFL recon failed.

## DURING PROCEDURE

The patient underwent arthroscopic left knee ACL reconstruction with peroneus longus autograft - standard portals with accessory medial portal:

- Femoral and tibial tunnels were drilled.
- Grafts were harvested and prepared.
- 8 mm peroneus longus graft was used for ACL reconstruction.
- Lateral meniscal repair was done side to side, all inside.
- Medial meniscus was normal.

Medial Patellofemoral Ligament (MPFL) reconstruction - mini open - was done with semitendinosus autograft.

- 7 mm graft, 2 suture anchors were placed in patella medially, schottle's point identified under c-arm and drilled, graft fixed with 25 mm bio screw.
- The ACL graft was passed and fixed, patella tracking was checked, and the MPFL graft was tightened. Wash was given and closed with staples.
- Range of motion knee brace was given.

### Intra-op Images





## POST PROCEDURE

The patient tolerated the procedure well and was in a stable condition on discharge. Sutures were removed 2 weeks after surgery. ROM was 20-80 degrees 3 weeks after the surgery. ROM exercises were delayed for 2 weeks to avoid stress on the MPFL reconstruction. Weight-bearing was delayed for 1 month due to the lateral meniscal repair.

### Plan:

By 6 weeks post-op, we wanted to achieve:

- 0-110 deg Range of movement (ROM)
- Strengthen quadriceps muscles
- Active straight leg raise with the knee in full extension

The patient did a few sessions of physiotherapy and was lost to follow up. He came to the OPD after 8 months of surgery. He had full knee range of motion, no instability, could squat and knee fully and jog without feeling any giving way of the patella or the knee. His quadriceps were still weaker compared to the normal side. He was advised to strengthen the Vastus Medialis Obliquus and quadriceps muscles and proprioception exercises and avoid games that involved cutting movements like football.

### Follow-up Images



## DISCUSSION

Concomitant management of these 2 common injuries is rare. We could only find a few papers on the topic, and most were a series of 1-3 cases.

All the authors have had good outcomes with the combined reconstruction of the ACL and MPFL. Careful planning of the steps and meticulous execution are required to balance stability and mobility, as both these surgeries and delayed rehabilitation can cause knee joint stiffness.

Rehabilitation is the most crucial factor here, and it has to be staged so as not to cause joint laxity. Overzealous physiotherapy can also lead to laxity and instability again.

Though our patient was irregular in his physiotherapy, he has a good, stable knee 6 months post-surgery.

## CONCLUSION

Combined ACL and MPFL reconstruction is a good procedure with favourable outcomes. It should be considered when such a rare case is encountered. It leads to shorter rehab time and faster recovery.

## REFERENCES


1. Wu Xiulin, Chen J, Ye Z, et al. Clinical and Radiological Outcomes After Combined ACL and MPFL Reconstruction Versus Isolated ACL Reconstruction for ACL Injury With Patellar Instability. 2024 Mar;52(4):936-947. doi: 10.1177/03635465241226976.
2. Kumar R, Harna B, Arya S. Simultaneous ACL and Patellofemoral Instability: Surgical Management and Outcomes. 2024 Apr;14(4):99–104. doi: 10.13107/jocr.2024.v14.i04.4374.
3. Hiemstra LA, Kerslake S, Heard M, et al. Outcomes of surgical stabilization in patients with combined ACL deficiency and patellofemoral instability - A case series. 2016 Dec;23(6):1106-1111. doi: 10.1016/j.knee.2016.08.006.
4. Shankar V, Hussain SN, Sahanand S, Rajan D. Concurrent Anterior Cruciate Ligament and Medial Patellofemoral Ligament. Reconstruction: A Case Report and Literature Review. 2020 Apr 18;12(4):e7717. doi: 10.7759/cureus.7717.
5. Macura M, Veselko M. Simultaneous reconstruction of ruptured anterior cruciate ligament and medial patellofemoral ligament with ipsilateral quadriceps grafts. 2010 Sep;26(9):1258-62. doi: 10.1016/j.arthro.2010.06.018.

Aster
HOSPITAL
We'll Treat You Well

Introducing

# Robotic Knee Joint Replacement System

Mankhool





**KEY BENEFITS:**

- Greater Precision
- Quicker Recovery
- Customised Surgery
- Improved Implant Longevity
- Minimal Scarring
- Less Pain & Blood Loss

04 400 500 asterhospitals.ae

Download my Aster