Aster HOSPITALS & CLINICS
We'll Treat You Well

HealthNews DIGEST

DECEMBER 2024



4 Hamatometacarpal Fracture Dislocation

7 Transforaminal Lumbar Interbody Fusion (TLIF)

11 Severe Aortic Stenosis

17 Acne and its Management

25 Gynecomastia



Dr. Sherbaz Bichu

CEO & Specialist Anaesthetist
Aster Hospitals & Clinics, UAE

On behalf of Aster's leadership, I am pleased to welcome you to the 28th edition of the HealthNews Digest. It is encouraging to see the ongoing zeal and dedication to this initiative. It has produced many educational materials for readers, offering insightful information and knowledge that deepens our comprehension of the medical field.

The HealthNews Digest has developed into a vital resource for Aster to uphold its dedication to clinical quality and information sharing. I am confident that the outstanding team of Aster doctors will keep lending their knowledge and commitment to this, expanding our comprehension of the medical domain and helping mould the future of healthcare.

As we explore unique clinical cases and thought-provoking articles, we can significantly impact patients' lives and continue to raise the bar in clinical excellence.



Dr. Ramanathan V

Medical Director
Aster Hospitals & Clinics, UAE

As the Medical Director for Aster Hospitals and Clinics, I am delighted to greet all our doctors as we commence the 28th edition of HealthNews. Witnessing their dedication and hard work in tackling complex and challenging cases and their commitment to finding solutions and improving patient outcomes is fascinating.

The medical field is constantly evolving, and it is through the efforts of our doctors that we are advancing medical knowledge and fostering innovation; our tenacity and unwavering resolve in the face of demanding medical challenges exemplify the essence of healthcare excellence.

I enthusiastically applaud the encouragement to continue producing outstanding achievements in medical science and contribute to subsequent HealthNews Digest editions.

Successful Treatment of Hamatometacarpal Fracture-Dislocation with Closed Reduction and Screw Fixation at Aster Hospital, Muhaisnah



Dr. Masoodh Basha
Orthopaedics (Specialist)

PRESENTATION

- 23 year old female
- History of slip and falling in bathroom 2 days back; sustained injury over the right wrist
- No comorbidities/ past surgery
- Presented with complaints of:
  - Swelling and pain over the right wrist

FINDINGS

During Examination:

- Right wrist - swelling and tenderness over the ulnar border and 5th metacarpal base

X-ray showed:

- Malalignment of the 5th ray with ?fracture of base of 5th metacarpal

CT Scan showed:

A coronal oblique intra-articular two-part fracture of the distal aspect of the body of the hamate was noted with a fracture line along the dorsal aspect with a displaced fracture of the anterolateral cortex of the base of the 5th metacarpal. Foreshortening of the 5th metacarpophalangeal joint was noted.

The 5th metacarpal base was wedged into the hamate fracture.

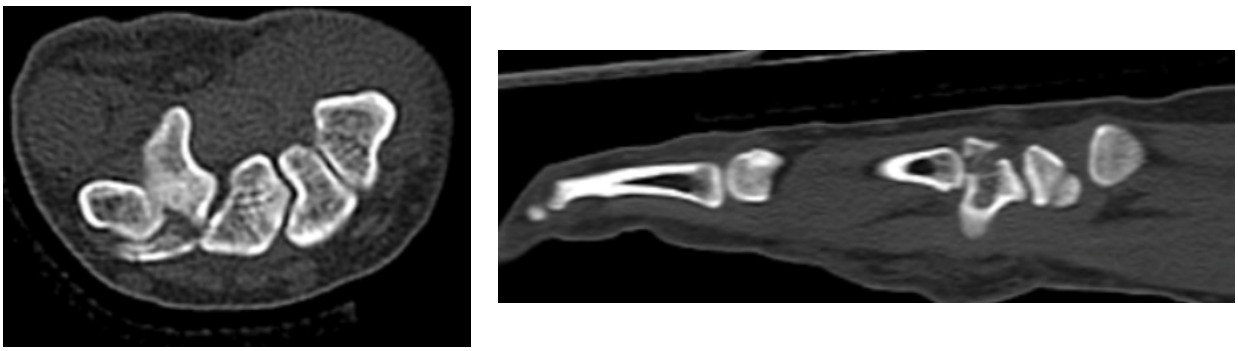

Pre-op CT Images



Pre-op CT Images



Pre-op X-ray Images

DURING PROCEDURE

The patient underwent closed reduction and K-wire fixation of 5th metacarpal base and screw fixation of the hamate.

- Under regional block and C-arm guidance, traction was applied to the 5th finger to disengage the metacarpal base from the hamate fracture.
- The 5th metacarpal base was then reduced and fixed with K-wires through the 5th to 4th metacarpal base.
- The hamate was fixed through a mini dorsal approach with one headless cannulated cancellous screw.

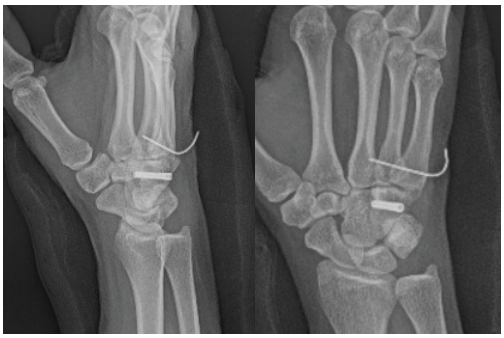

Intra-op Images

POST PROCEDURE

The patient tolerated the procedure well. She was on regular follow-up for two months in the outpatient department. The slab was kept for a week, and sutures were removed on post-op day 12.

The K-wire was removed after 4 weeks. The patient had complete functional recovery in one month after the K-wire removal.



Follow-up images

DISCUSSION

This atypical injury has been presented for the rarity of its occurrence and difficulty in diagnosis. It can be easily missed on the X-ray. High suspicion is needed in a patient not getting better after injury. Malalignment of the rays, absence of the CMC joint line, and fracture fragments need to be looked for on the X-ray. A low threshold for CT should be observed.

Hamatometacarpal fracture dislocations are classified as follows:

Type IA - Subluxation or dislocation of the fifth carpometacarpal joint without hamate avulsion fracture.

Type IB - Type IA lesions + small dorsal rim hamate avulsion fracture.

Type II - Subluxation or dislocation of the fifth carpometacarpal joint and the dorsal hamate rim comminution.

Type III - Coronal splitting of the hamate.

This patient had a type III injury.

CONCLUSION

There are very few reported cases of a 5th metacarpal fracture displaced into a hamate fracture. The mechanism is usually an axial loading force along the metacarpal. Delays or failures to diagnose and treat can lead to deformities, stiffness, and significant loss of grip strength in the affected hand. Hence, careful history and examination, careful reading of X-rays, and a CT scan when in doubt can lead to early diagnosis and treatment of these unusual hamatometacarpal fracture-dislocations.

REFERENCES

1. Amine H, Reda L, Assouab O, et al. Hamatometacarpal fracture-dislocation: A case report. ScienceDirect. Elsevier. Trauma Case Reports. Volume 48, December 2023. doi: 10.1016/j.tcr.2023.100966.
2. Syed AA, Agarwal M, Giannoudis PV, Matthews SJ. Dorsal hamatometacarpal fracture-dislocation in a gymnast British Journal of Sports Medicine. Oct 2002. 36:380-382. doi: 10.1136/bjsm.36.5.380.
3. Jr Cain JE, Shepler TR, Wilson MR. Hamatometacarpal fracture-dislocation: classification and treatment. J Hand Surg Am. 1987 Sep;12(5 Pt 1):762-767. doi: 10.1016/s0363-5023(87)80064-3.
4. Bhardwaj P, Sivakumar BS, Vallurupalli A, et al. Fracture dislocations of the carpometacarpal joints of the fingers. J Clin Orthop Trauma. 2020 Jun 9;11(4):562–569. doi: 10.1016/j.jcot.2020.05.039.
5. Austin RE, Pennings AL, ElMaraghy AW. Intraosseous Fifth Carpometacarpal Dislocation Associated with a Coronal Hamate Fracture: A Case Report. JBJS Case Connect. 2014 Sep 10;4(3):e76. doi: 10.2106/JBJS.CC.M.00035.
6. Wharton DM, Casaletto JA, Choa R, Brown DJ. Outcome following coronal fractures of the hamate. J Hand Surg Eur Vol 2010 Feb;35(2):146-9. doi: 10.1177/1753193408098907.

A Comprehensive Overview of Transforaminal Lumbar Interbody Fusion (TLIF)



Dr. Prakash Nair
Neurosurgery (Consultant)
Aster Hospital, Mankhool

INTRODUCTION

Lower back pain (LBP) is a prevalent condition that affects individuals across all age groups, with an estimated 619 million people impacted globally (1). LBP manifests with symptoms such as dull or sharp pain radiating from the back to the legs, often accompanied by numbness, tingling, or muscle weakness (1). This significantly impacts the quality of life and reduces productivity (2). LBP can be classified based on its duration as acute (<6 weeks), sub-acute (6–12 weeks), or chronic (>12 weeks) (2). However, untreated chronic LBP can progress to severe complications, including disability, muscle atrophy, and nerve damage, ultimately leading to lumbar spine diseases (2).

Currently, medications, physical therapy, and lifestyle modifications are standard treatments for managing chronic pain (2). However, when these approaches prove inadequate in providing sufficient relief, transforaminal lumbar interbody fusion (TLIF) offers a targeted surgical option in carefully selected patients (2). This procedure enhances spinal stability while reducing compression over the neural structures. TLIF can be performed through either an open or minimally invasive approaches providing benefits such as preserving anatomical structures, promoting biomechanical stability, and ultimately offering effective relief for degenerative lumbar conditions (3).

This article will provide an overview of the evidence supporting TLIF in managing lower back pain and examine its outcomes.

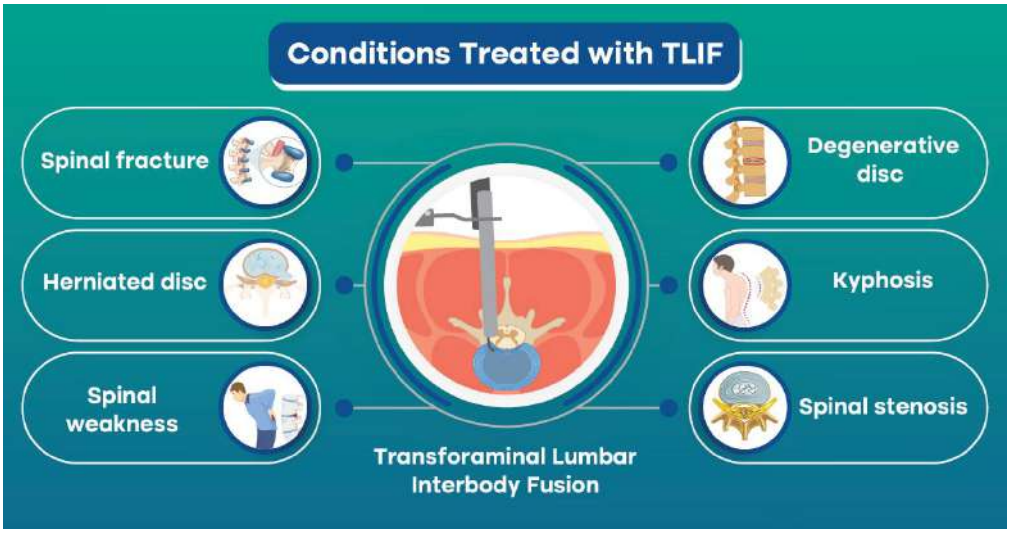

Figure 1: Diseases managed with transforaminal lumbar interbody fusion (TLIF)

TYPES OF TLIF PROCEDURES:

- **Open Surgery TLIF:**

During open TLIF surgery, the patient is positioned prone to reduce epidural venous engorgement (3). Proper C-arm imaging is used to ensure alignment of the spinous process and parallel endplates in both anteroposterior and lateral views (3). A small 2-3 cm paramedian incision is made approximately 5 cm from the midline (3). Jamshidi needles are then inserted at the intersection of the transverse process and superior facet, followed by guidewire implantation, sequential dilation, and pedicle screw insertion (3). A pre-contoured rod is placed on the less favorable side, while a temporary distraction is applied to the other side (3).

After carefully retracting the nerve root, the thecal sac is exposed through an ipsilateral hemilaminectomy and near-complete facetectomy (3). During the subsequent discectomy and endplate preparation, the bone graft is packed before being placed into a graft-filled cage (3). The rod is then secured, the temporary distraction is removed, and the incision is closed in layers (3).

- **Robot-Assisted TLIF:**

In robotic-assisted lumbar surgery, the patient is positioned prone on a radiolucent table for optimal screw placement and imaging (4). Navigation posts are placed in the posterior superior iliac spines, and intraoperative CT imaging guides the screw trajectories (4). After confirming the appropriate trajectory, robotic-guided pedicle screws are inserted through a transverse incision (4). The robotic arm positions the tubular retractor to enhance visibility for discectomy and cage placement (4). Finally, a pre-contoured rod is secured under fluoroscopy guidance, and the incision is closed in layers (4).

Robotic-assisted TLIF offers various benefits compared to open surgery TLIF, such as less intraoperative blood loss, shorter hospital stay, and a reduced complication rate (5). However, robotic-assisted TLIF may take longer operational time due to its technical complexities (5). Nevertheless, the reduced tissue stress and faster recovery associated with the robotic approach help to overcome this disadvantage (5). The key differences between open-surgery TLIF and robotic-assisted TLIF are summarized in Figure 2 (5).

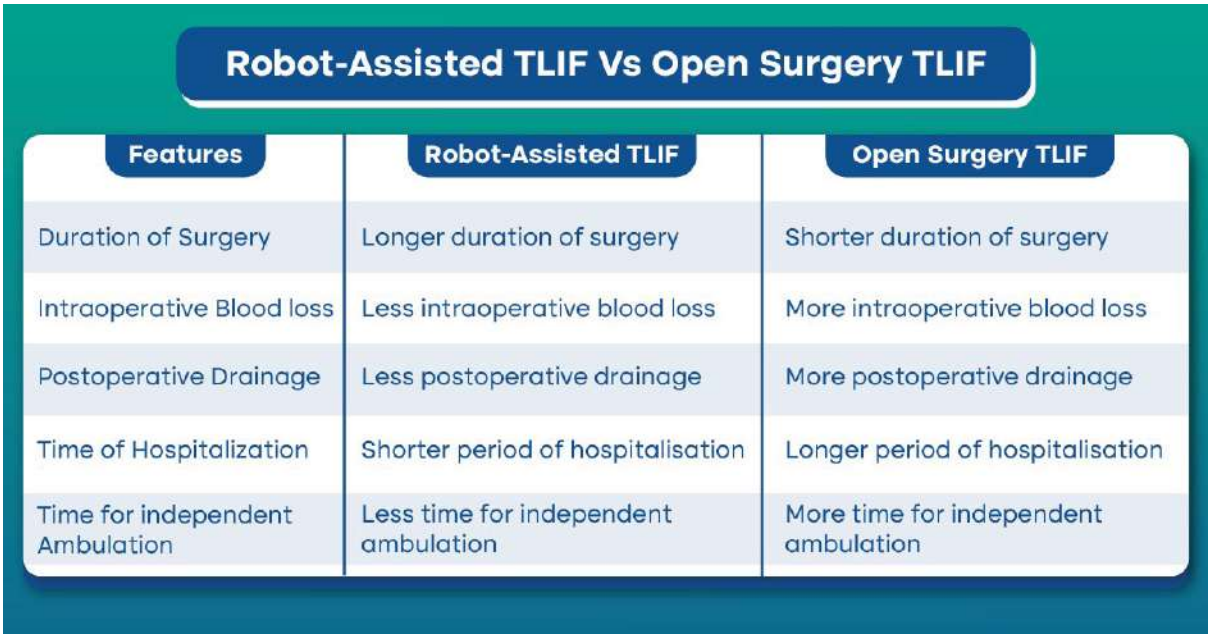

Figure 2: Difference between Open Surgery and Robot-Assisted Surgery

EFFECTIVENESS AND SAFETY OF TLIF:

TLIF is an effective surgical option for the management of lumbar degenerative disc disease, spondylolisthesis, severe lumbar stenosis, and disc herniation, particularly when standard conservative treatment fails (5). The MIS-TLIF is gaining prominence due to its minimized disruption of bone and muscle structures, resulting in reduced blood loss, tissue trauma, and faster patient recovery (5). Both MIS-TLIF and open TLIF procedures have demonstrated significant long-term improvements in functional outcomes, as evidenced by Visual Analog Scale (VAS) and Oswestry Disability Index scores (ODI) (6). Additionally, TLIF effectively restores spinal alignment by re-establishing lumbar and segmental lordosis, which is essential for biomechanical stability (6). Magnetic Resonance Imaging (MRI) studies have revealed reduced damage to multifidus muscle with the MIS-TLIF approach, showing its muscle-sparing advantages (5).

A comparative study involving 145 patients, with 76 undergoing open TLIF and 69 receiving MIS-TLIF, showed no significant demographic differences between the groups, showed no significant demographic differences between groups. The average follow-up duration was 35.8 months for open TLIF and 37.9 months for MIS-TLIF (5). However, open TLIF group had a significantly higher rate of double-level surgeries (P=0.013) (5). While the MIS-TLIF group had a longer average operation time (170.1 vs. 130.8 minutes; P<0.0001), they also exhibited reduced blood loss (139.6 mL vs. 289.7 mL; P<0.0001) and a shorter hospital stay (4.9 vs. 5.5 days; P=0.002) (5).

Postoperative outcomes demonstrated significant improvement in VAS and ODI scores for both groups, with no significant differences in recovery metrics (P=0.0612 for VAS, P=0.820 for ODI) (5). Additionally, both techniques resulted in significant enhancements in lumbar and focal lordosis, while pelvic incidence remained stable (5). Complication rates were similar across the groups, with 11.8% in the open TLIF group and 13% in the MIS-TLIF group, and revision surgeries were performed as needed (5).

ADVANCES IN TLIF:

- **Percutaneous Endoscopic Transforaminal Lumbar Interbody Fusion (PETLIF):**

PETLIF enhances vision during TLIF through direct viewing of the disc space, thereby reducing the risk of nerve and vascular injury (7).

Comparative studies of PETLIF and traditional MITLIF show less intraoperative blood loss and improved postoperative pain in PETLIF than in the MITLIF cohort (7). Furthermore, patients with grade 1 spondylolisthesis who underwent PETLIF showed significant disc correction and successful fusion without complications at 12 months follow-up (7). Additional advantages of PETLIF include reduced surgical impact and pain, lower blood loss and faster recovery (7).

PETLIF, like any other spinal procedure, faces several limitations, such as limited visualization and higher radiation exposure (7). Additionally, the endoscopic technique had a steep learning curve, though operative times tend to improve over time while maintaining comparable outcomes and minimal disease recurrence (7).

- **The Transfacet Lumbar Interbody Fusion (TF-LIF):**

TF-LIF is a type of MIS-TLIF that allows access to the disc space via the bony corridor of the facets, lowering the risk of nerve injury that is commonly associated with percutaneous methods (7). By removing the superior articular process, this method allows direct visibility of the disc during disc preparation and other percutaneous treatments while avoiding nerve root exposure (7).

Studies have reported promising findings regarding TF-LIF's impact on spinopelvic alignment, back pain, and functional outcomes (7). Significant enhancements in disc height, segmental lordosis, and overall lumbar lordosis have been observed (7). While a small proportion of patients experienced subsidence, the majority achieved successful spinal fusion within one year (7).

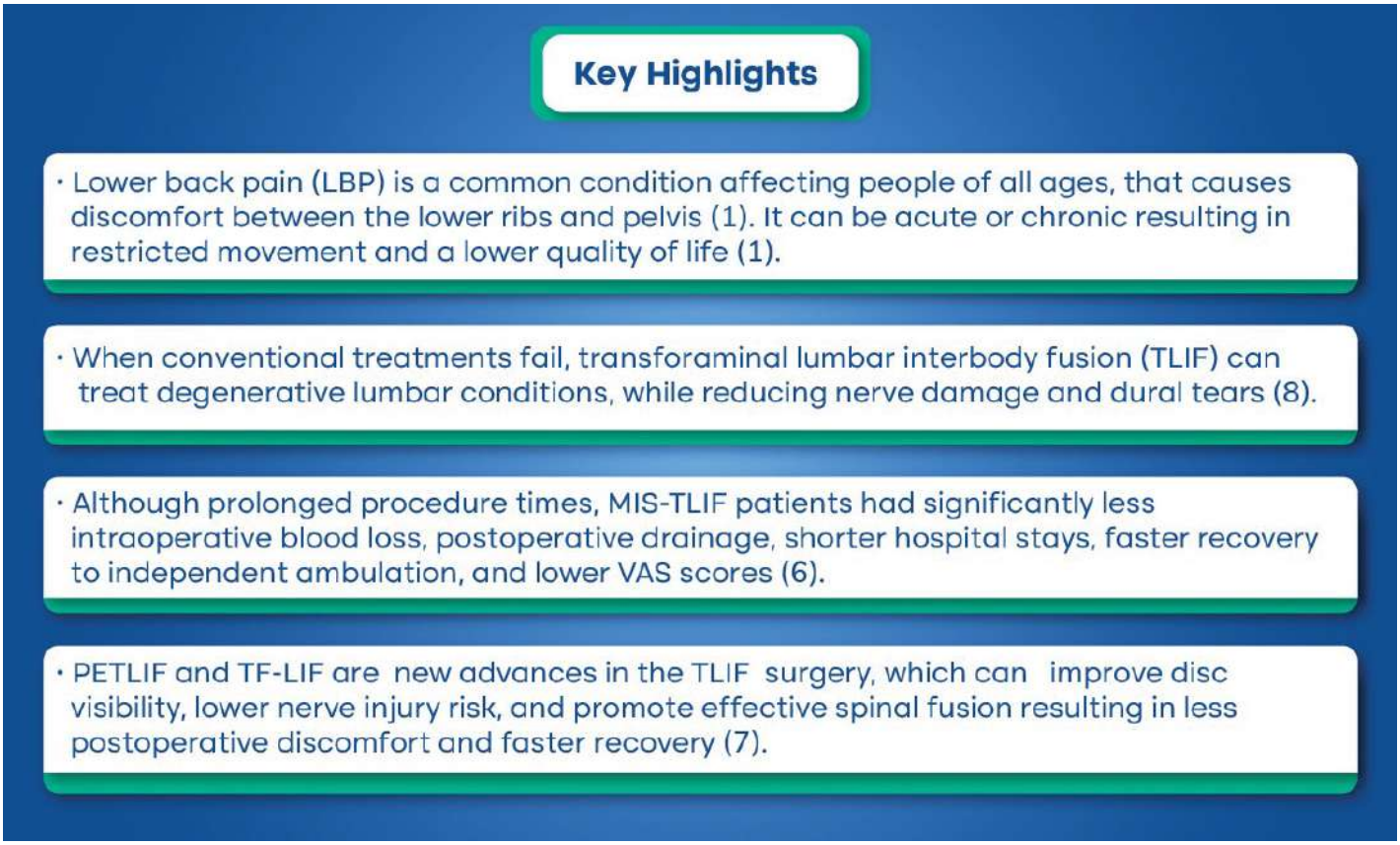

REFERENCES

1. Low back pain [Internet]. [cited 2024 Oct 28]. Available from: https://www.who.int/news-room/fact-sheets/detail/low-back-pain
2. Ho EKY, Chen L, Simic M, Ashton-James CE, Comachio J, Wang DXM, et al. Psychological interventions for chronic, non-specific low back pain: systematic review with network meta-analysis. BMJ. 2022 Mar 30;e067718.
3. Garg B, Mehta N. Minimally invasive transforaminal lumbar interbody fusion (MI-TLIF): A review of indications, technique, results and complications. J Clin Orthop Trauma. 2019 Jan 14;10(Suppl 1):S156.
4. Sarmiento JM, Shahi P, Melissaridou D, Fourman MS, Araghi K, Qureshi SA. Step-by-step guide to robotic-guided minimally invasive transforaminal lumbar interbody fusion (MI-TLIF). Ann Transl Med. 2022 Dec 22;11(5):221.
5. Modi HN, Shrestha U. Comparison of Clinical Outcome and Radiologic Parameters in Open TLIF Versus MIS-TLIF in Single- or Double-Level Lumbar Surgeries. Int J Spine Surg. 2021 Oct 1;15(5):962–70.
6. Hartmann S, Lang A, Lener S, Abramovic A, Grassner L, Thomé C. Minimally invasive versus open transforaminal lumbar interbody fusion: a prospective, controlled observational study of short-term outcome. Neurosurg Rev. 2022 Oct 1;45(5):3417–26.
7. Drossopoulos PN, Ononogbu-uche FC, Tabarestani TQ, Huang CC, Paturu M, Bardeesi A, et al. Evolution of the Transforaminal Lumbar Interbody Fusion (TLIF): From Open to Percutaneous to Patient-Specific. J Clin Med. 2024 Jan;13(8):2271.
8. Peck J, Urits I, Peoples S, Foster L, Malla A, Berger AA, et al. A Comprehensive Review of Over the Counter Treatment for Chronic Low Back Pain. Pain Ther. 2021 Jun 1;10(1):69–80.



Dr. Naveed Ahmed
Interventional Cardiology (Consultant)
Aster Hospital, Mankhool



Dr. Abdul Rauoof Malik
Cardiology (Specialist)
Aster Hospital, Al Qusais



Dr. Krishna Sarin MS Nair
Interventional Cardiology (Specialist)
Aster Hospital, Al Qusais

A case of Severe Aortic Stenosis with CAD, Hypertension with CKD in Atrial Fibrillation treated successfully with Transcatheter Aortic Valve Replacement (TAVR) and Percutaneous Coronary Intervention (PCI) at Aster Hospital, Al Qusais

PRESENTATION

- A 76-year-old male with severe aortic stenosis (AS), coronary artery disease (CAD), and heart failure with preserved ejection fraction (HFpEF)
- Atrial fibrillation (AFib) for 2 months - on rate control and anticoagulant therapy
- Presented with worsening dyspnea - NYHA class IV - and intermittent left-sided chest discomfort. Also, h/o hemoptysis present.
- Recent admission at another facility for unstable angina with acute decompensated heart failure (ADHF) - coronary angiogram showed CAD and was advised CABG+AVR
- Long-standing hypertension, chronic atrial fibrillation, chronic kidney disease (CKD), and chronic venous insufficiency s/p 3 varicose vein surgeries complicated by chronic cellulitis
- Recent h/o acute cholecystitis and sepsis

CLINICAL EXAMINATION

- Afebrile, conscious and oriented
- Vitally stable with BP - 104/56 mmHg; HR - 68/min
- CVS: S1, S2 heard, irregular; ejection systolic murmur grade 3/6 at LUSE
- RS: Bilateral basal rales

INITIAL ASSESSMENT AND MANAGEMENT

- ECG: AFib with controlled ventricular rate
- Serial troponins within normal limits
- Chest X-ray: Cardiomegaly, vascular redistribution, diffuse ground glass opacification, bilateral pleural effusion
- CT thorax (for h/o hemoptysis): minimal bilateral pleural effusion, few fibrotic parenchymal bands with architectural distortion, possibly sequel of previous pulmonary tuberculosis
- NT-Pro BNP: Elevated
- Echocardiogram: Severe calcific aortic stenosis. Mild aortic regurgitation. Moderate mitral regurgitation. Moderate-to-severe tricuspid regurgitation. Moderate pulmonary hypertension. Concentric LV hypertrophy. No RWMA. LVEF ~ 63%. No clot/ effusion.

The patient was admitted and managed for HFpEF with gradual up-titration of medication. This resulted in the resolution of symptoms and diuresis. X-ray showed marked resolution of pulmonary venous congestion and interstitial opacifications.

CT scan to assess suitability for transcatheter aortic valve replacement (TAVR) in view of high surgical risk status (age 76 yrs, STS score 48, comorbidities - HTN, HLP, CAD, Anemia - Hb 8.6 gm/dl). A detailed discussion was held with the patient and bystander, and the patient was counselled to undergo TAVR and Percutaneous Coronary Intervention (PCI). He was ambulated without chest pain or shortness of breath on walking and was discharged stable.

The patient was readmitted 2 weeks later for elective PCI and TAVR. Apixaban was stopped and replaced with enoxaparin. For severe mid and distal right coronary artery disease, PCI using two drug-eluting stents was done.

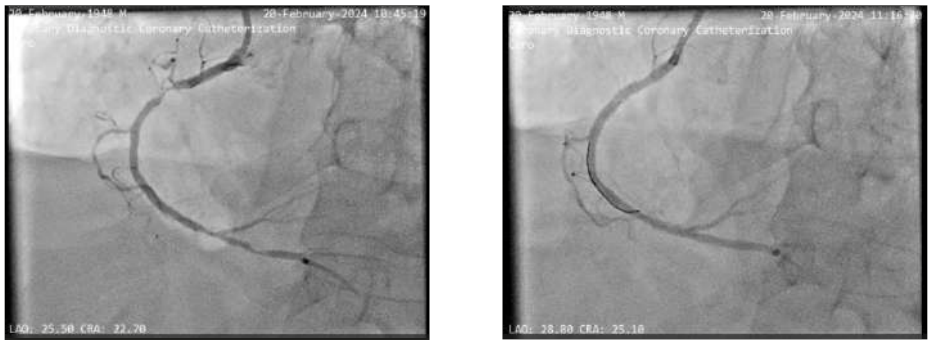

(A) (B)

Figure 1. Right coronary angiogram before (A) and after (B) stenting

In view of underlying CKD, adequate hydration was performed pre- and post-procedure. The patient was taken up for TAVR under conscious sedation via left femoral artery (FA) access as the main access for the 14F sheath. Right FA and right femoral vein (FV) accesses were used for pigtail catheter placement and temporary cardiac pacing, respectively.

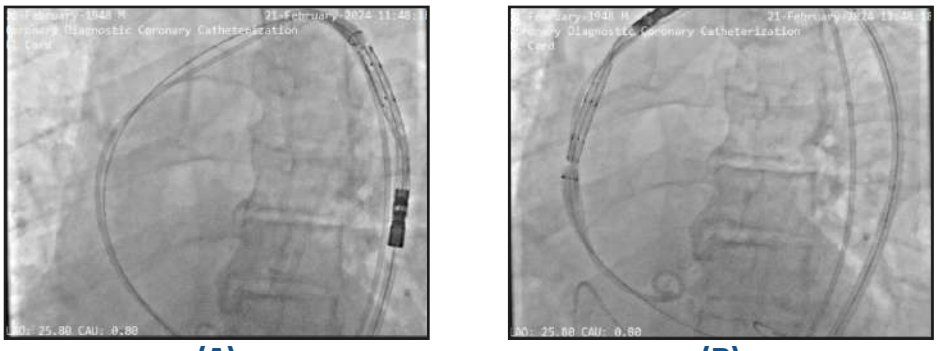

(A) (B)

Figure 2. TAVR procedure. The delivery system can be seen in descending (A) and ascending (B) aorta

A successful 26 mm Hydra self-expanding valve was deployed under temporary pacing, followed by a final aortogram showing mild aortic regurgitation and good results. The valve was post-dilated with a 22 mm balloon.

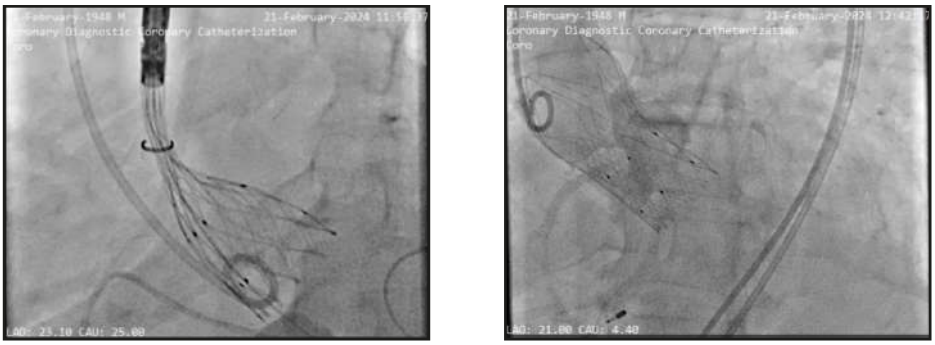

(A) (B)

Figure 3. TAVR procedure. The partially expanded (A) and fully deployed (B) TAVR device

The left groin was closed with ProGlide. The right groin sheath was manually compressed. At the end of the procedure, peripheral pulses were monitored and were well felt.

POST PROCEDURE

The patient was shifted to the ICU for further monitoring. Two units of red cells were transfused. He improved symptomatically, was mobilised, and remained stable throughout the hospital stay. There was a new onset of left bundle branch block (LBBB) during the procedure (soon after the balloon dilatation), which persisted afterwards with no progression to advanced conduction blocks. The patient was discharged on day 3 in hemodynamically stable condition. Twenty-four-hour Holter after 2 weeks did not show any atrioventricular block. The patient was advised triple antithrombotic therapy for 1 week; this was de-escalated to clopidogrel and apixaban for a year. The patient is on regular outpatient follow-up and can carry out his daily activities without any dyspnea or chest pain.

DISCUSSION

Aortic stenosis (AS) is the most common cause of left ventricular outflow tract obstruction. The disease remains latent until there is a critical narrowing of the aortic valve, at which time the classic symptoms of angina, syncope and heart failure may become evident. Severe AS is a potentially fatal condition, especially among symptomatic patients, with most untreated patients dying within 2-3 years after diagnosis. Surgical aortic valve replacement (SAVR) has been the classical standard treatment for patients with severe AS. For the patients deemed to be too high risk to undergo SAVR, the outlook may be especially grim. Historically, such patients would only be offered palliative treatment in the form of diuretics and, sometimes, balloon aortic valvuloplasty (BAV)as temporising measures. Although BAV achieved favourable acute hemodynamic outcomes, restenosis and clinical deterioration occurred in most cases within 6-12 months, necessitating repeat procedures. To address these limitations, the concept of transcatheter aortic valve replacement (TAVR), where a bioprosthetic valve was sewn into a stenting scaffold, was developed and repeatedly tested in animal models.

Professor Alain Cribier performed the first-in-human TAVR procedure at Charles Nicolle University Hospital in Rouen, France, on April 16, 2002. His patient, a 57-year-old male in cardiogenic shock having LVEF 12% with previous lung cancer, chronic pancreatitis, and leg ischaemia, who had been declined by 3 cardiac surgery teams - was transferred from the University Hospital in Lille for an emergency BAV, a procedure also introduced by Dr. Cribier and colleagues in 1986 as an alternative treatment for inoperable patients with severe AS. After some initial hemodynamic improvement with BAV, there was a recurrence of shock at 48 hours. This prompted the use of percutaneous valve replacement as the only possible option to save life. The patient had remarkable hemodynamic improvement after the procedure, with good valvular function and no recurrence of heart failure

for 4 months, at which time he died from severe noncardiac complications. Nevertheless, the remarkable technical success was encouraging and resulted in subsequent feasibility studies.

In the following years, TAVR emerged as an effective treatment option in inoperable patients with severe AS, riding on a strong evidence base generated from a series of randomised controlled trials (RCTs) (Table 1). The initial trials compared TAVR to medical therapy in inoperable or extreme-risk patients and demonstrated superiority. Subsequent RCTs compared TAVR to SAVR in high and intermediate-surgical risk patients, and TAVR was found to be non-inferior in all studies. Encouraged by these findings, RCTs of low surgical-risk patients were conducted, which demonstrated similar positive results favouring TAVR. Thus, TAVR developed into an effective therapy that dramatically changed the outlook for patients with severe AS, especially those considered to be inoperable, reducing both the intractable symptoms as well as the risk of death.

Trial (Year)	Population (N)	Primary Results
Partner 1, Cohort B (2010)	Inoperable (358)	TAVR was "Superior" to medical therapy in reducing "death from any cause at 1 year"
CoreValve Extreme Risk (2014)	Inoperable (471)	TAVR achieved its primary endpoint of a low rate of all-cause mortality or major stroke at one year that compared favorably to a "rigorously defined" objective performance goal
Partner 1, Cohort A (2011)	High risk (699)	TAVR was non-inferior to SAVR in reducing death from any cause at 1 year
Corevalve High Risk (2014)	High risk (790)	TAVR was superior to SAVR in reducing death from any cause at 1 year
Partner 2 A (2016)	Intermediate risk (2032)	TAVR was non-inferior to SAVR in reducing death from any cause or major stroke at 2 years
Surtavi (2017)	Intermediate risk (1660)	TAVR was non-inferior to SAVR in reducing death from any cause or major stroke at 2 years
Partner 3 (2019)	Low risk (1000)	TAVR was superior to SAVR in reducing the composite endpoint of death, stroke, or rehospitalization at 1 yr
Evolut Low Risk (2023)	Low risk (1403)	TAVR was non-inferior to SAVR in reducing all-cause mortality or disabling stroke at 24 months

Table 1. Landmark Trials in TAVR

THE TECHNIQUE

The TAVR procedure delivers a fully collapsible replacement valve through a catheter to work as a valve-within-valve without removing the damaged native valve. Once the new valve is expanded, it pushes the old valve leaflets out of the way, and the tissue in the replacement valve controls blood flow. Computed tomography angiography of the chest, abdomen, and pelvis is also performed to help determine the valve size and visualize the vascular anatomy. Left heart catheterization is commonly done prior to TAVR for invasive hemodynamic measurements and to rule out any coexisting CAD that may need revascularization.

The currently available transcatheter aortic valves are balloon-expandable or self-expandable and use bovine or porcine pericardial tissue. The Hydra valve (Sahajanand Medical Technologies Limited, Mumbai, India) used in the present case is a self-expanding valve that has three tentacle-like components to optimize conformability to the aorta and large open frame cells to facilitate easier coronary access.

The TAVR procedure is typically done in a hybrid room with operating room and cath lab capabilities. Typically, the procedure is done under local anesthesia with conscious sedation. The most preferred and least invasive approach is the transfemoral approach. If not feasible, the minimally invasive transapical approach may be used, or more rarely, the more invasive and technically challenging subclavian, trans-caval, trans-carotid, trans-aortic or trans-septal approaches. In some patients, the TAVR valve can push aside an old valve flap, causing coronary artery obstruction - a rare but life-threatening complication of TAVR that can be prevented through the newly developed transcatheter BASILICA procedure.

Possible complications to TAVR include conduction disturbances (which can necessitate a permanent pacemaker), vascular site complications, annular rupture, left ventricular perforation, cardiac tamponade, acute myocardial infarction, acute kidney injury, hypotension, and death. Paravalvular aortic regurgitation is common after TAVR, but refinements in the procedure and prosthesis design have dramatically reduced its incidence. Some operators routinely use embolic protection devices to reduce stroke risk, although their utility has been challenged lately. TAVR has now been done in thousands of patients worldwide with a procedural success rate of 90%. The 30-day mortality rates have varied from 3-15%. Early deaths are usually due to arrhythmias, heart failure and pulmonary complications.

FOLLOW-UP

Transcatheter heart valves (THV), being tissue valves, have the inherent potential to fail. As TAVR is increasingly used in lower-risk patients with a longer life expectancy, cases of TAVR bioprosthetic valve failure could arise. Clinical studies have shown stable mean aortic valve gradients and a low incidence of valve degeneration at 5 years follow-up. Intraprocedural strategies such as pre-dilatation, appropriate valve sizing, and avoidance of post-dilatation may improve leaflet longevity. Newer bioprosthetic platforms, including modifications in leaflet material and designs, have been developed to limit the structural deterioration of THV. As of today, cases of bioprosthetic failure can be managed with SAVR or valve-in-valve redo TAVR.

ELIGIBILITY AND INDICATIONS

Current society guidelines only recommend aortic valve replacement for patients with symptomatic severe AS or asymptomatic patients with very severe AS, left ventricular systolic dysfunction, or markedly elevated BNP. An interprofessional heart team evaluates patients for TAVR candidacy. The regulatory level eligibility of AS patients for TAVR has been changing since the procedure's clinical adoption. Initially, TAVR was reserved for patients at high or prohibitive risk for SAVR based on the Society of Thoracic Surgeons-predicted risk of mortality (STS PROM) model for SAVR. In 2015, the indication was expanded to include a "valve-in-valve" procedure for failed surgical bioprosthetic valves. As the clinical trials continued to demonstrate the safety and efficacy of TAVR in comparison to SAVR in different patient groups, TAVR eligibility was expanded in 2016 to include intermediate-risk patients (STS PROM scores >3%) and again in 2019 to include younger low-surgical-risk patients with STS PROM scores ≤3%.

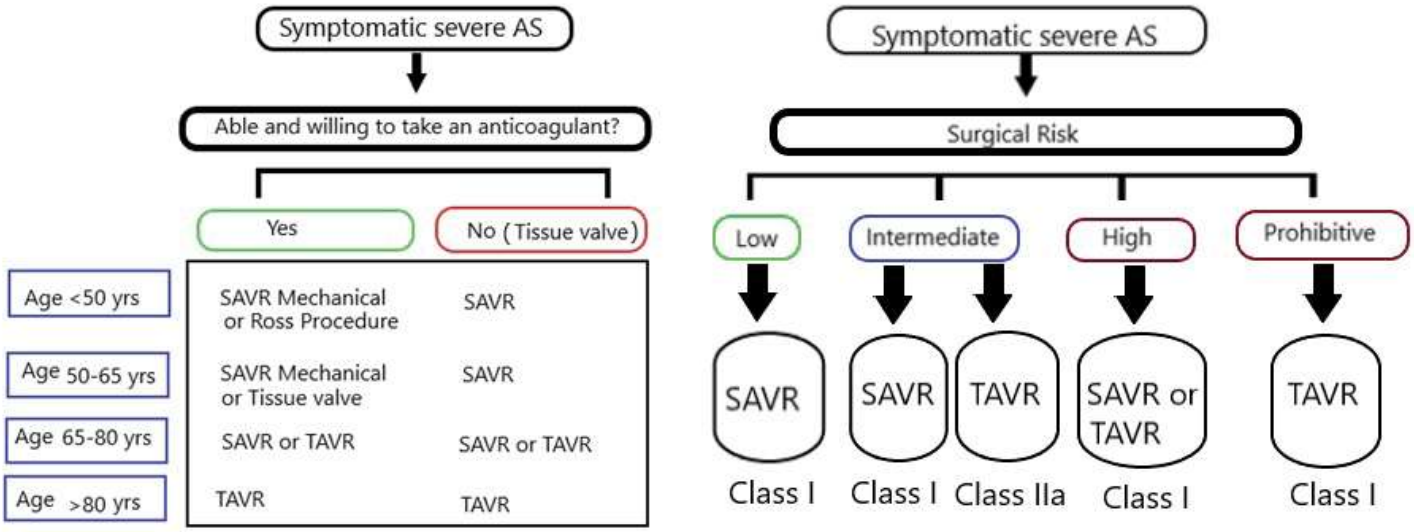

Figure 4. Common considerations for replacing the aortic valve in severe aortic stenosis

EVOLVING INDICATIONS

As the operative technique and hardware used in TAVR are further refined and the evidence continues to build on its effectiveness across the spectrum of risk severities in AS patients, the global usage of TAVR is expected

to rise exponentially. For example, intervention for asymptomatic severe AS not meeting criteria remains controversial. Two recent studies – AVATAR and RECOVERY – have shown that compared to conservative management, early SAVR among asymptomatic patients with severe AS significantly reduced the risk of operative or cardiovascular mortality, heart failure, acute myocardial infarction, or stroke at 4 years. In the just-published EARLY TAVR trial, among patients with asymptomatic severe AS, a strategy of early TAVR was superior to clinical surveillance in reducing the incidence of death, stroke, or unplanned hospitalization for cardiovascular causes. Additionally, many patients cannot undergo SAVR due to excessive surgical risk in lieu of factors not included in the current risk assessment algorithms, including porcelain aorta, severe lung or liver disease, frailty, and hostile mediastinum, among other factors. TAVR has been used as an alternative to relieve symptoms and extend life in such patients.

CONTRAINDICATIONS

- Patients with a life expectancy of less than 12 months owing to a noncardiac cause
- Myocardial infarction within the last 30 days
- Need for emergency surgery
- The need for concomitant coronary artery bypass grafting
- Severe pulmonary hypertension with right ventricular dysfunction
- Echocardiographic evidence of intracardiac mass, thrombus or vegetation
- MRI confirmed CVA or TIA within the last six months
- End-stage renal disease

Patients having congenital unicuspid, bicuspid or noncalcified valve, hypertrophic cardiomyopathy, short distance between the annulus and coronary ostium, unsuitable aortic annulus diameter, severe mitral regurgitation, mixed aortic valve disease (concomitant aortic regurgitation), or significant aortic disease are also not considered suitable candidates for TAVR. Furthermore, mechanical valves can only be implanted surgically; therefore, a transcatheter approach is not appropriate for patients deemed more suitable for mechanical valve replacement.

CONCLUSION

In patients with severe AS, TAVR has emerged as a ground-breaking alternative to traditional open-heart surgery, primarily designed for elderly and inoperable patients. However, in numerous trials, TAVR matched or surpassed surgery for patients with diverse surgical risk profiles. As a result, TAVR is now being routinely applied to a broadening spectrum of patients. Although long-term follow-up data and the applicability to younger patients are still uncertain, accumulating clinical and research data and refinements in hardware and technique are expected to greatly influence the evolving landscape of indications for TAVR and our management of patients with severe AS.

REFERENCES

1. Cribier A, Eltchaninoff H, Bash A, et al. Percutaneous transcatheter implantation of an aortic valve prosthesis for calcific aortic stenosis: first human case description. Circulation. 2002;106(24): 3006-3008. doi: 10.1161/01.cir.0000047200.36165.b8
2. Srinivasan A, Wong F, Wang B. Transcatheter aortic valve replacement: Past, present, and future. Clin Cardiol. 2024;47:e24209. doi: 10.1002/clc.24209.
3. Vinayak M, Leone PP, Tanner R, et al. Transcatheter Aortic Valve Replacement: Current Status and Future Indications. J. Clin. Med. 2024, 13, 373. doi: 10.3390/jcm13020373.
4. Raheem S, Popma JJ. Clinical Studies Assessing Transcatheter Aortic Valve Replacement. Methodist Debakey Cardiovasc J. 2012;8(2):13–18. doi: 10.14797/mdcj-8-2-13.
5. Généreux P, Schwartz A, Oldemeyer JB, et al. Transcatheter Aortic-Valve Replacement for Asymptomatic Severe Aortic Stenosis. N Engl J Med. 2024 Oct 28. doi: 10.1056/NEJMoa2405880.

Brief Overview of Acne and its Management



Dr. Rakesh Kumar Mishra
Dermatology (Specialist)
Aster Cedars Hospital, Jebel Ali

INTRODUCTION

Acne vulgaris, commonly known as pimples, is a persistent skin inflammatory problem having widespread global prevalence with an estimated incidence of 9.4% (1). It is the 8th largest skin disease that affects adolescents as well as adults (1). Acne affects the pilosebaceous unit of the skin, causing either inflammatory or noninflammatory lesions (1,2). Acne primarily appears on the face, neck, upper back and chest (3). There are several types of acne ranging from papules to cysts (1). Patients suffering from acne experience poor physical and psychological health making its treatment critical (4).

This article briefly discusses the risk factors, histopathology, types of acne, and treatment options.

RISK FACTORS AND PATHOPHYSIOLOGY OF ACNE DEVELOPMENT

There are various risk factors involved in the formation of acne (5). They are listed below in the table below:

Factors Responsible for Acne

Risk factors	Causes
Individual factors	Gender, age, economic status, heredity, obesity, skin type, menstrual cycle (in females), high glycemic diet, smoking, use of cosmetics and electronic products, sleep quality, and psychological factors, stress
Environmental factors	Temperature and humidity
Social factors	Lifestyle changes, dietary habits, exposure to air pollution, consumption of sugary foods, irregular sleep patterns, and stress
Hormonal imbalance	Hormonal changes during adolescence, pregnancy, and menopause, androgen excess disorders including PCOS, congenital adrenal hyperplasia, adrenal or ovarian tumors, Cushing syndrome, seborrhea, hirsutism and androgenetic alopecia
Genetic	Family history of acne
Disorders	Apert syndrome, Synovitis acne pustulosis hyperostosis osteitis, Behcet syndrome, Pyogenic Arthritis, Pyoderma gangrenosum and Acne syndrome, Acne medicamentosa, SAPHO syndrome
Drugs	Danazol, testosterone, progestin, glucocorticoids, lithium, isoniazide, phenytoin, Vitamins B2, B6, and B12, halogens, and EGF inhibitors

Table 1. Risk factors for Acne (6,7)

The primary acne lesion is microcomedeon, a small hyperkeratotic plug containing corneocytes located in the lower region of the follicular infundibulum, which acts as a precursor for acne (2). It gradually evolves to different types of acne lesions (2). The steps of microcomodon formation are depicted in the image below:

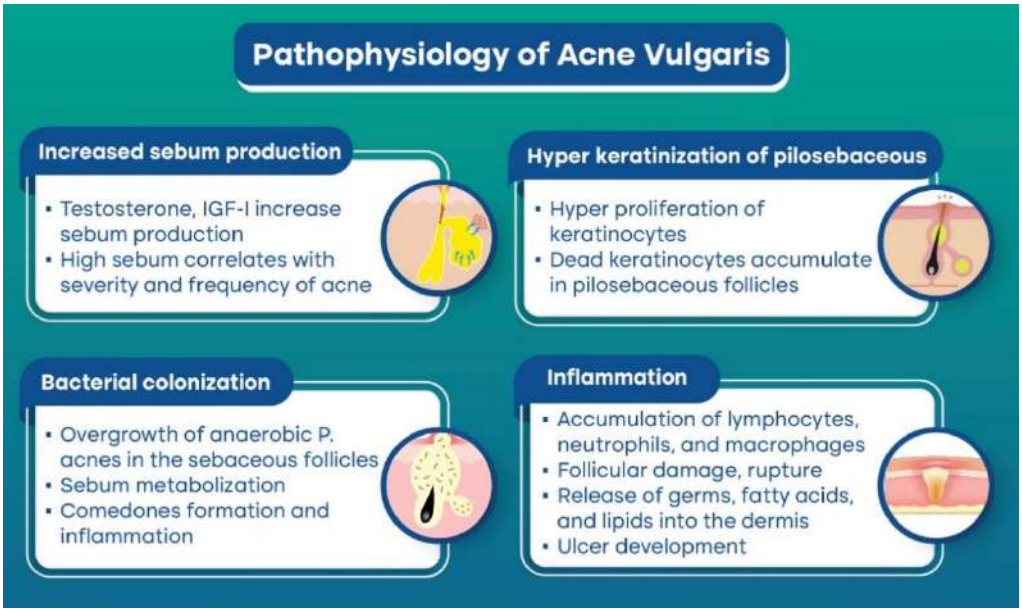

Figure 2: Pathophysiology of Acne

IGF-1: insulin like growth factor-I, P. acne: Propionibacterium acne (7)

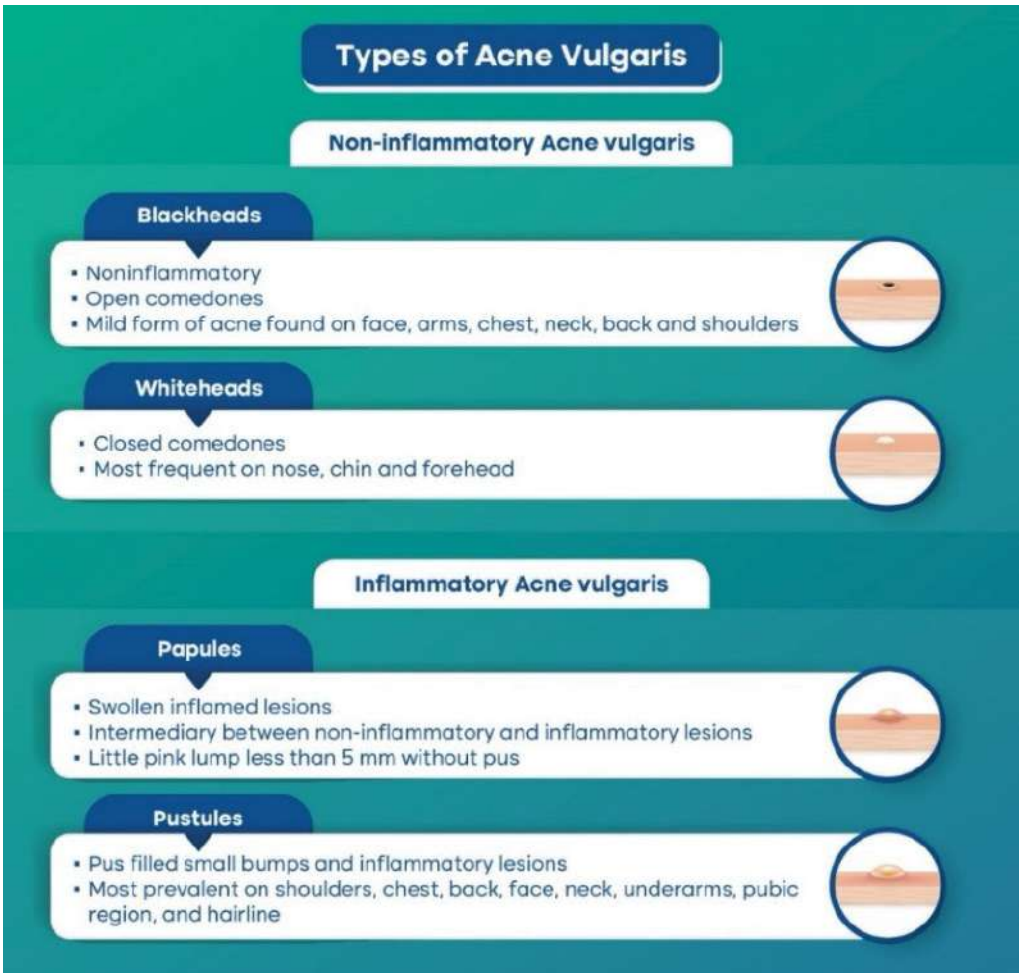

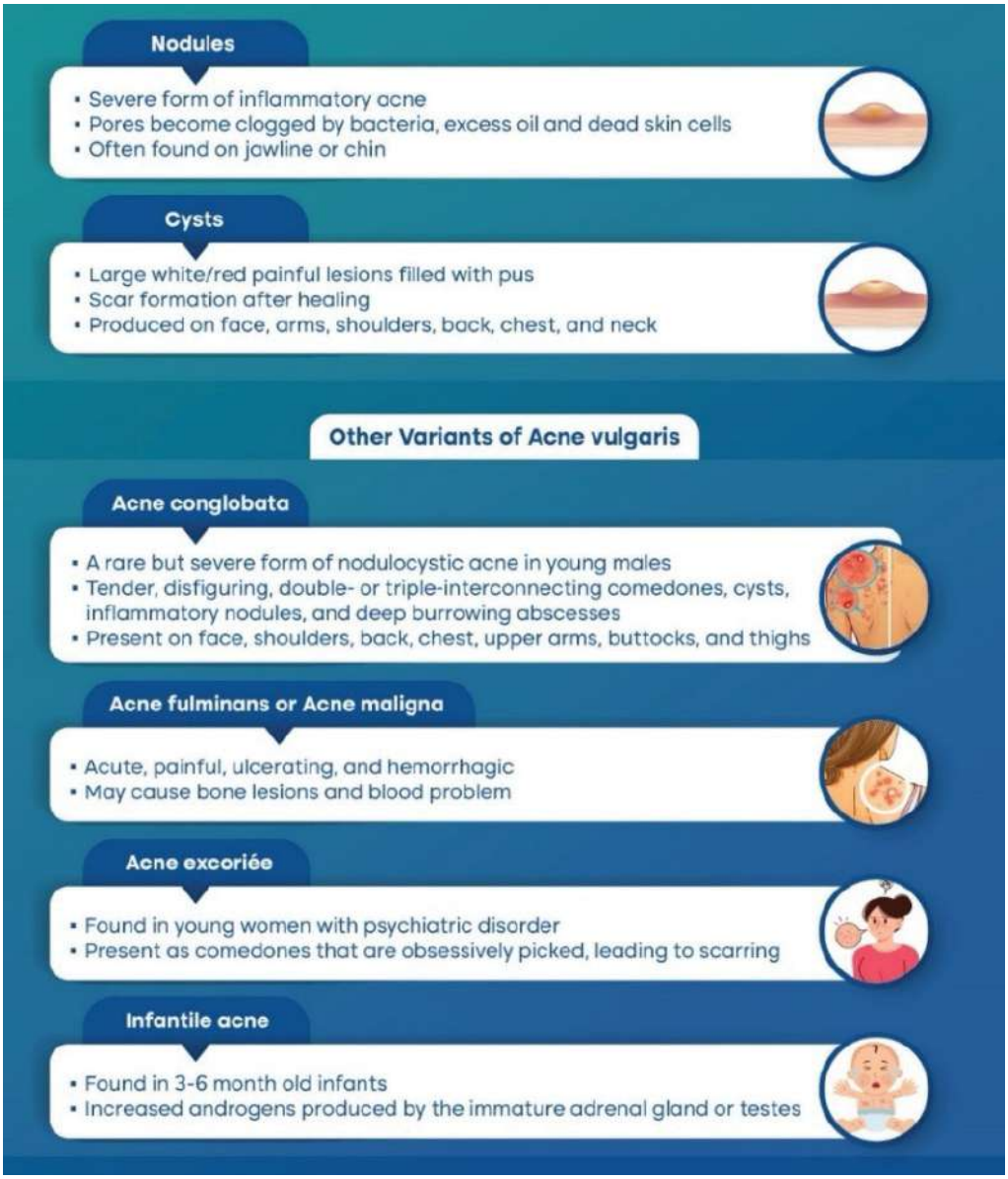

Figure 3: Different Types of Acne Vulgaris (1)

ACNE MANAGEMENT

Acne negatively affects patient's self-image and self-esteem during their adolescent age and can lead to the development of anxiety, depression, social isolation, stigmatization, bullying and suicidal tendencies (4). Persistent acne in adulthood may affect employment opportunities, lower their social status, relationships, and daily activities (4). Acne patients can have a significantly impaired quality of life, comparable to individuals suffering from asthma, epilepsy, diabetes, back pain, or arthritis (4). The management of acne primarily focuses on treating current acne, shortening its duration, preventing permanent scar formation, and minimizing the recurrence (3). The acne treatment mainly include antibiotics and anti-inflammatory drugs that would control sebum secretion, abnormal hyperkeratinization of the pilosebaceous follicles and Propionibacterium infection (3).

A. CONVENTIONAL MEDICATION

1. Topical treatment

Topical treatments available as gel, cream, lotion, and emulsion forms are mostly employed for mild to moderate acne (1). In contrast to systemic absorption, topical ointments increase the exposure to the

pilosebaceous units, hence are more effective (1). Patient's age, affected area, and the extent and severity of lesions could be useful in deciding the choice of topical treatment (3). Some of the commonly used topical treatments are discussed below:

i. Retinoids:

Retinoids are mostly used for treating inflammatory or noninflammatory acne and are considered as a mainstay of treating refractory acne cases (1). They act by reducing sebum production, regulating comedone formation, rebuilding the damaged epithelium, treating hyperpigmentation, heal scarring, reducing acne lesions, and controlling the growth of existing comedones (1). The US FDA has approved tretinoin, adapalene and tazarotene for acne management (8).

Treatinoin is a first-generation retinoid used in combination with other retinoids to normalize the epithelial layer, prevent occlusion of the pilosebaceous unit and reduce sebum production (1). Adalpene a first generation and tazoretene, a second-generation retinoid are useful for reducing the hyperkeratinisation and hyperproliferation of P. acne in the epithelial layer of acne (1). Patients prescribed with retinoids should be advised to avoid direct sunlight and wear sunscreen (8). Retinoids are not recommended during pregnancy (3).

ii. Azelaic acid:

It possesses antibacterial, anti-inflammatory, anti-keratolytic, comedolytic, and anti-oxidative properties, it also has a whitening effect due to inhibition of tyrosinase enzyme (3). A recent study showed that 15% azelaic acid gel is as effective as 0.1% adapalene gel in treating inflammatory acne in adult women (3). Azelaic acid is well tolerated, non-teratogenic and can be used in lactating women (3).

iii. Salicylic acid:

It is a mild anti-inflammatory, comedolytic fungistatic and bacteriostatic agent (3). Salicylic acid is a useful alternative to topical retinoids in treating mild acne for those who are unable to tolerate or obtain them (1).

iv. Benzoyl peroxide:

Benzoyl peroxide is an FDA-approved treatment for acne vulgaris (9). It is a topical nonantibiotic disinfectant that can be combined with antibiotics and retinoids (1). It also possesses anti-inflammatory and keratolytic properties (3).

2. Antibiotics

As microbial colonization and inflammation are mainstay of acne, using topical antibiotics that have both antimicrobial and anti-inflammatory activity are useful to diminish acne lesions (3). The American Academy of Dermatology also suggest oral antibiotics act as a first-line treatment for moderate to severe form of acne such as acne fulminans and acne conglobate (3). Tetracyclines such as doxycycline and minocycline are effective in the treatment of acne (10). Erythromycin and clindamycin should be prescribed only in patients who are contraindicated to tetracyclines (10). Due to the increased risk of resistance, it is advisable to combine antibiotics with benzoyl peroxide and retinoids whenever possible (3). Additionally used antibiotics for acne treatment are minocycline, fusidic acid, bacitracin, gentamicin, mupirocin, cephalosporins, penicillin, and trimethoprim-sulfamethoxazole etc. (3,1).

3. Hormone Therapy

Cystic, nodular, dispersed lesions and sudden onset acne despite normal menstrual period should be considered as hormonally induced acne (11). Hormonal therapies are effective for such types of as well as severe acne forms (11). Patients who present with such severe forms of acne should undergo an endocrine evaluation to rule out other factors (11). Drugs used in the hormonal treatment of acne fall into four major categories: androgen receptor blockers, oral contraceptives, glucocorticoids and 5α-reductase inhibitors, these drug classes function by reducing androgen production thereby reduce the sebum formation and acne (11).

An important consideration is to stop other hormonal treatments one month before evaluation to avoid false results (11). Insulin resistance also causes hyperandrogenism hence insulin-sensitizing agents like metformin should be prescribed for patients with PCOS, HAIR-AN syndrome, obesity and hyperinsulinemia (11). Hormonal

therapy should be used in combination with retinoids and antibiotics for patients with thrombophilic disorders are contraindicated to oral contraceptives (3).

B. EMERGING THERAPIES FOR ACNE MANAGEMENT

There has been significant progress in new therapies for acne management that can overcome the side effects and bacterial resistance of conventional drugs (12, 3). Some of these therapies are listed below:

1. Topical Treatment

i. Clascoterone cream

This is an FDA-approved androgen receptor inhibitor topical cream for acne vulgaris in patients 12 years and above (13). Phase III clinical trial studies have shown good efficacy of twice daily application of clascoterone in reducing facial acne (13).

ii. Tranexamic acid

This is a synthetic derivative of lysine that inhibits plasminogen to plasmin conversion, reduces blood clotting, and is useful for mild to moderate acne (3). It also improves the post-inflammatory erythema induced by acne (3).

iii. Meclizine gel

A histamine receptor antagonist and anti-emetic drug, that has recently been shown to be an effective anti-acne medicine (14).

iv. Ivermectin

This drug alleviates lipopolysaccharide-mediated inflammation caused by *P. acnes* (3). 1% ivermectin cream can improve lipopolysaccharide-mediated inflammation from acne (3).

2. Alternative Systemic Treatment

i. Oral probiotics:

The anti-acne activity is exhibited by suppressing cytokine IL-8 production in epithelial cells and keratinocytes immunomodulatory effect (3). Studies have shown that combined therapeutic use is more effective (3).

ii. Biological agents:

TNF-α inhibitors adalimumab and etanercept are useful for severe nodular acne and acne fulminans (3).

IL-17 and IL-23 inhibitors manage SAPHO syndrome (3).

3. Physical Therapy

i. Laser and light therapy:

It is useful for those experiencing adverse effects from other acne medication and do not respond to conventional treatments (3). It reduces number of inflammatory acne lesions, sebum output, and inflammatory cytokine (3). Red and blue light therapy function by stimulating the porphyrins of *P. acnes* thereby destroy them (3). They work synergistically with antibiotics to reduce inflammation (3).

ii. Mesotherapy:

It is a process of directly injecting cosmetic active ingredients into dermis or deeper subcutaneous layers that are affected with acne(15). This approach improves the metabolism and quality of skin from within and thereby helps to heal resistant acne(15). A study demonstrated that injecting glycyrrhizin via mesotherapy is more effective than clindamycin for treating moderate to severe acne (15).

iii. Carbon laser:

This painless method destroys the causative agent of acne P acne and atrophies the sebaceous glands and decreases sebum production (16). Carbon laser therapy is quick and efficient for destroying treatment resistant acne (16). The additional advantage of this method includes anti-inflammatory action and neo-collagenesis that

improves the skin texture and acne scar remodeling (16). This method can also cure pigmentation and scarring resulting from acne (17) .

iv. Derma pen and microneedling with PRP injections:

The process of microneedling creates numerous tiny holes in the skin surface, when combined with platelet-rich plasma (PRP) this method encourages collagen and new cell production (18). PRP is a rich source of growth factors that act synergistically with local growth factors induced by skin needling and enhances wound healing (19). This method is more effective than microneedling with vitamin C in treating atrophic acne scars (19). Derma pens are similar to microneedle, this method also creates micro injuries in the skin that trigger a healing cycle of collagen induction, and elastin to fill the injuries that rejuvenate the skin and texture (20).

v. Dermal fillers:

Derma fillers are injected in skin to raise the depressed areas of acne scars or stimulate skin's natural collagen production (21). The fillers can be categorized as temporary (eg. hyaluronic acid), semi-permanent (eg. calcium hydroxyapatite, poly-L-lactic acid) or long lasting (eg. silicone, polymethylmethacrylate, polyacrylamide, and polyalkylimide) (22). These fillers can be injected by various methods such as droplet injection, linear threading, fanning, or three-dimensional volumization would be useful (22).

4. Non-pharmacological Treatment

i. Chemical peels:

In this method a controlled epidermal and dermal injury is introduced which promotes skin regeneration and remodeling to manage acne lesions (3). Salicylic acid 30% peel reduces oil secretion, unclog pores, and mitigates pimple formation (3). Glycolic acid, alpha-hydroxy peels exfoliate the skin surface, reduces inflammation, and suppress P. acnes (3). Trichloroacetic acid eliminates the outer layer of old skin and reduces acne scar (3). It also stimulates collagen production and fosters smoother skin regeneration (3).

ii. Diet:

Impact of diet on acne could vary from race and ethnicity (23). Studies show that high glycemic diet increase acne while low glycemic diet reduces it (3, 23). Increased dairy product consumption may have pro-acnegenic effects in some populations (23).

MANAGEMENT OF ACNE COMPLICATIONS

Following are the specific issues that arise from acne inflammation and possible ways to manage them:

- **Hyperpigmentation:** To reduce hyperpigmentation photoprotection, topical treatments with retinoids, azelaic acid, and hydroquinone, and chemical peels of glycolic acid or salicylic acid are useful (2).
- **Erythema:** Topical 5% tranexamic acid, pulsed-dye laser, fractional micro-needling radiofrequency, and pulsed light therapy can be used (2).
- **Ice-pick scars:** For reducing the ice pick scars, chemical reconstruction using trichloroacetic acid, punch elevation or excision, ablative fractional laser or erbium resurfacing is recommended (2).
- **Rolling scars:** Subcision, filler injection, needle-free pneumatic solution injection help reduce rolling scars. For contoured scars, ablative fractional laser with subcision can be combined (2).
- **Boxcar scar:** To repair boxcar scars, excision, erbium laser, needle-free pneumatic solution injection, and filler injection can be useful (2).
- **Hypertrophic scar or keloid:** Radiotherapy, cryotherapy, surgical excision and intralesional injection of triamcinolone, 5-fluorouracil are useful for pulsed dye laser or intense pulsed light therapy (2).
- **Papular scars:** CO_2 laser vaporization and light electrodesiccation can be an effective way to reduce papular scars (2).

MISCONCEPTIONS ABOUT ACNE

Some common misunderstandings about acne vulgaris are:

1. **Acne does not require medical attention.** This is not true because if untreated, acne can aggravate chronic diseases and transform into some other disease forms (16, 17).
2. **Diet modification causes acne.** There is no scientific evidence that consuming junk foods cause acne. Chocolate, french fries and other junk foods have little or no effect on acne (16, 17).
3. **Acne is caused by uncleanliness.** Most of the stages of acne occur beneath the skin, and not on the surface, hence cleanliness of skin does not affect acne (16, 17).
4. **Treatment rapidly improves acne.** It's not true, acne treatment can be time consuming sometimes (16, 17).
5. **Acne can be treated by sunlight.** The sunlight can inflame and dry the skin, which causes it to produce more oil, making acne episode worse (24).
6. **Only oily skin is prone to acne.** Acne affects all different skin types that suffer from acne. Whiteheads, blackheads and pimples can be found in all skin types (16, 17).

MISCONCEPTION ABOUT SELF-TREATMENT FOR ACNE

1. **Popping pimples:** it triggers inflammatory responses and can introduce even more bacteria and can also cause scars which don't go away (25).
2. **Applying toothpaste on acne:** Drying acne with toothpaste and other household items is not safe for skin (25). The fluorides present in toothpaste can even worsen the acne (25).
3. **Exfoliation:** Scrubbing face hard doesn't wash away the acne (25). In fact this can lead to inflamed acne, making it even worse (25).

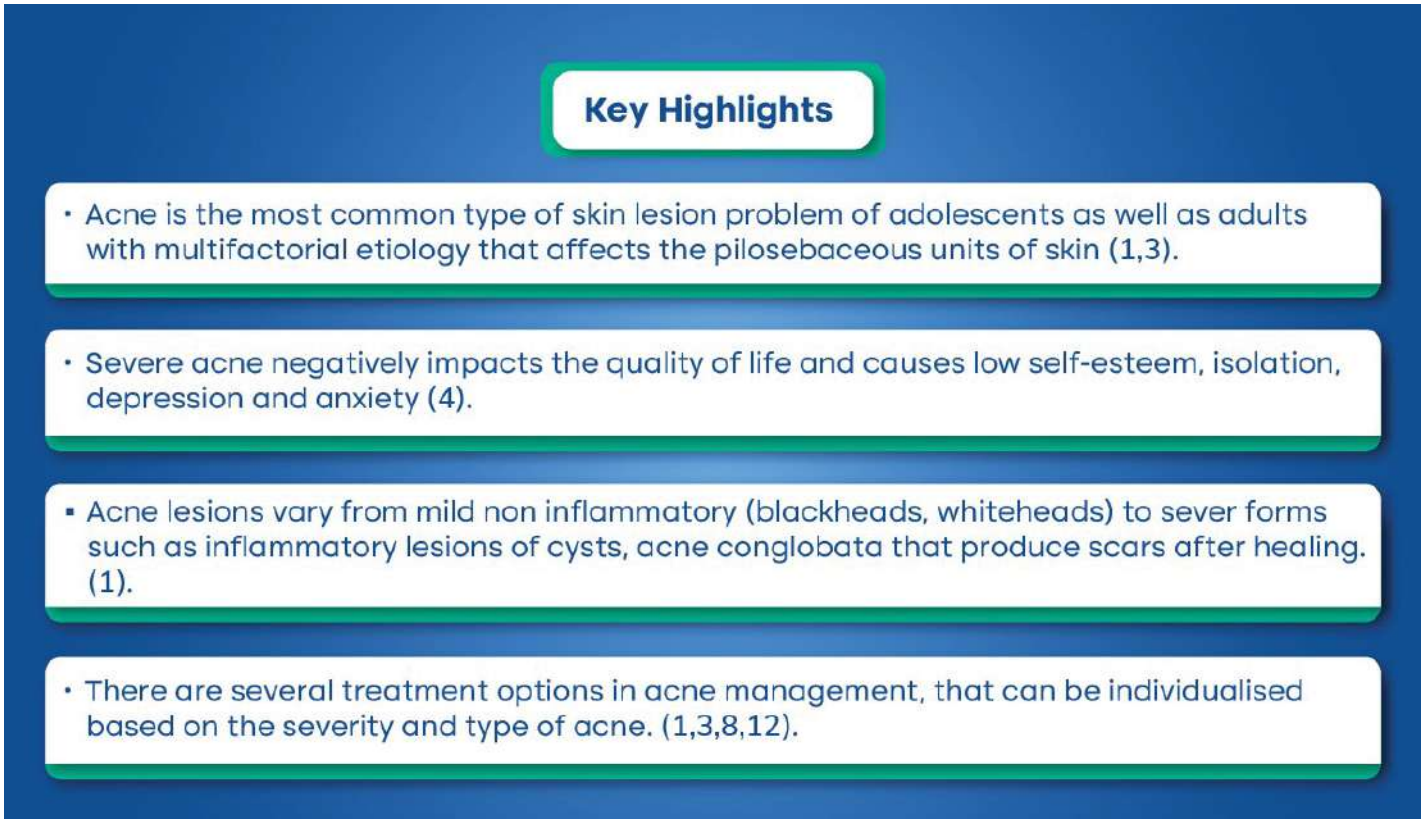

REFERENCES

1. Vasam M, Korutla S, Bohara RA. Acne vulgaris: A review of the pathophysiology, treatment, and recent nanotechnology based advances. Biochem Biophys Rep. 2023;36:101578. Available from: https://www.sciencedirect.com/science/article/pii/S2405580823001590
2. Sutaria AH, Masood S, Saleh HM, Schlessinger J. Acne Vulgaris. In: StatPearls [Internet]. Treasure Island (FL): StatPearls Publishing; 2024. Available from: http://www.ncbi.nlm.nih.gov/books/NBK459173/
3. Li Y, Hu X, Dong G, Wang X, Liu T. Acne treatment: research progress and new perspectives. Front Med . 2024;11. Available from: https://www.frontiersin.org/journals/medicine/articles/10.3389/fmed.2024.1425675/full
4. Gieler U, Gieler T, Kupfer Jp. Acne and quality of life – impact and management. J Eur Acad Dermatol Venereol. 2015;29(S4):12–4. Available from: https://onlinelibrary.wiley.com/doi/abs/10.1111/jdv.13191
5. Yang J, Yang H, Xu A, He L. A Review of Advancement on Influencing Factors of Acne: An Emphasis on Environment Characteristics. Front Public Health. 2020;8:450. Available from: https://pmc.ncbi.nlm.nih.gov/articles/PMC7527424/
6. Lolis MS, Bowe WP, Shalita AR. Acne and Systemic Disease. Med Clin North Am. 2009;93(6):1161–81.Available from: https://linkinghub.elsevier.com/retrieve/pii/S0025712509001035
7. Jaiswal S, Jawade S, Madke B, Gupta S. Recent Trends in the Management of Acne Vulgaris: A Review Focusing on Clinical Studies in the Last Decade. Cureus 2024. 16(3):e56596. Available from: https://www.ncbi.nlm.nih.gov/pmc/articles/PMC11031619/
8. Latter G, Grice JE, Mohammed Y, Roberts MS, Benson HAE. Targeted Topical Delivery of Retinoids in the Management of Acne Vulgaris: Current Formulations and Novel Delivery Systems. Pharmaceutics. 2019;11(10):490. Available from: https://www.mdpi.com/1999-4923/11/10/490
9. Matin T, Patel P, Goodman MB. Benzoyl Peroxide. In: StatPearls [Internet]. Treasure Island (FL): StatPearls Publishing; 2024. Available from: http://www.ncbi.nlm.nih.gov/books/NBK537220/
10. Graber EM. Treating acne with the tetracycline class of antibiotics: A review. Dermatol Rev. 2021;2(6):321–30. Available from: https://onlinelibrary.wiley.com/doi/abs/10.1002/der2.49
11. Elsaie ML. Hormonal treatment of acne vulgaris: an update. Clin Cosmet Investig Dermatol. 2016 ;9:241. Available from: https://pmc.ncbi.nlm.nih.gov/articles/PMC5015761/
12. Auffret N, Claudel JP, Leccia MT, Ballanger F, Dreno B. Novel and emerging treatment options for acne vulgaris. Eur J Dermatol EJD. 2022;32(4):451–8. Available from: https://pubmed.ncbi.nlm.nih.gov/36301760/
13. Dhillon S. Clascoterone: First Approval. Drugs. 2020;80(16):1745–50. Available from: https://doi.org/10.1007/s40265-020-01417-6
14. Grange PA, Ollagnier G, Remigereau LB, Nicco C, Mayslich C, Marcelin AG, et al. A New Topical Candidate in Acne Treatment: Characterization of the Meclozine Hydrochloride as an Anti-Inflammatory Compound from In Vitro to a Preliminary Clinical Study. Biomedicines. 2022;10(5):931. Available from: https://pmc.ncbi.nlm.nih.gov/articles/PMC9138413/
15. Chen Y, Han W, Li S, Nie Y, Chen P, Sun J, et al. Effects of mesotherapy introduction of compound glycyrrhizin injection on the treatment of moderate to severe acne. J Cosmet Dermatol. 2023;22(7):1973–9. Available from: https://onlinelibrary.wiley.com/doi/abs/10.1111/jocd.15681
16. Bhatnagar A, Mitra D, Kishore K, Kumar M, Valarmathi T, Kumar A, et al. Efficacy of Carbon Peel Laser in Acne Vulgaris in Skin of Color: A Single Center Prospective Study. J Cutan Aesthetic Surg. 2023 ;16(3):205. Available from: https://pmc.ncbi.nlm.nih.gov/articles/PMC10768957/
17. Admin. Benefits of Carbon Laser Peel Treatment [Internet]. Orthodermaclinic. 2024. Available from: https://orthodermaclinic.com/what-does-a-carbon-laser-facial-do/
18. Microneedling with PRP: Benefits, side effects, and more [Internet]. 2019. Available from: https://www.medicalnewstoday.com/articles/327381
19. Chawla S. Split Face Comparative Study of Microneedling with PRP Versus Microneedling with Vitamin C in Treating Atrophic Post Acne Scars. J Cutan Aesthetic Surg. 2014;7(4):209. Available from: https://pmc.ncbi.nlm.nih.gov/articles/PMC4338464/
20. Dermapenworld. DermapenWorld. 2018. Dermapen For Acne. Available from: https://www.dermapenworld.com/blog/dermapen-for-acne-the-breakthrough-skin-rejuvenating-technique-for-clearer-skin
21. Healthline [Internet]. 2021. Fillers for Acne Scars: Procedure, Cost, and More. Available from: https://www.healthline.com/health/acne/fillers-for-acne-scars
22. Almukhadeb E, Binkhonain F, Alkahtani A, Alhunaif S, Altukhaim F, Alekrish K. Dermal Fillers in the Treatment of Acne Scars: A Review. Ann Dermatol. 2023;35(6):400. Available from: https://pmc.ncbi.nlm.nih.gov/articles/PMC10733075/
23. Meixiong J, Ricco C, Vasavda C, Ho BK. Diet and acne: A systematic review. JAAD Int. 2022;7:95–112. Available from: https://www.sciencedirect.com/science/article/pii/S2666328722000281
24. Hui RW. Common Misconceptions about Acne Vulgaris: A Review of the Literature. Clin Dermatol Rev. 2017;1(2):33. Available from: https://journals.lww.com/cddr/fulltext/2017/01020/common misconceptions about acne vulgaris a.1.aspx
25. Dermatology AA. Anne Arundel Dermatology. 2017. The Top 12 Acne Myths And Why They Aren't True. Available from: https://aadermatology.com/the-top-12-acne-myths/

Aster HOSPITALS & CLINICS
We'll Treat You Well

Anabolic Steroid-Induced Grade-2 Gynecomastia treated with Power-Assisted Liposuction and Trans-Nipple Gland Excision at Aster Hospital, Mankhool



Dr. Rajkumar Ramachandran
Plastic Surgery (Consultant)

PRESENTATION

- 26-year-old male
- Medical history of three years of anabolic steroid use for bodybuilding purposes, during which he reported significant muscle gain but also noted the gradual development of gynecomastia
- Admitted with complaints of:
  - Bilateral breast enlargement that has developed over the past six months

FINDINGS

Physical examination showed moderately enlarged breast tissue, classified as grade 2 gynecomastia according to the classification system proposed by Simon (1986), which includes mild to moderate breast tissue enlargement without significant skin excess.



Pre-operative images

PROCEDURE

The patient underwent power-assisted liposuction (PAL) to remove excess adipose tissue, followed by trans-nipple glandular excision to address the underlying glandular tissue:

- The patient was placed under general anaesthesia, and the surgery was performed through a cruciate incision over the nipple, which, when healed, would leave an inconspicuous scar.
- PAL was utilized to facilitate the removal of fatty tissue, while careful dissection allowed for complete excision of the glandular tissue.
- 300 mL of lipo-aspirate and 150 g of glandular tissue excised.

POST PROCEDURE

The patient tolerated the procedure well and was stable when discharged on the same day with appropriate post-operative care instructions. He was advised to wear compression garments for 4 weeks.



Post-operative images

DISCUSSION

Anabolic steroid-induced gynecomastia occurs due to the aromatization of excess testosterone to estradiol, leading to an imbalance in the estrogen-testosterone ratio. This imbalance stimulates breast tissue growth, particularly in predisposed individuals (1). The psychological impact of gynecomastia can be significant, affecting self-esteem and quality of life (2). In this case, the patient's decision for surgical intervention underscores the importance of addressing both the physical and psychological aspects of gynecomastia.

Grading of Gynecomastia:

Gynecomastia is typically graded based on the extent of breast tissue enlargement and associated characteristics. The Simon classification system, widely used in clinical practice, categorizes gynecomastia into three grades:

- **Grade 1 (Mild):** Slight breast tissue enlargement without excess skin, often presenting as a small amount of glandular tissue beneath the nipple.
- **Grade 2 (Moderate):** More pronounced breast tissue enlargement, characterized by a palpable mass of glandular tissue. There is usually no significant skin excess, and the breast shape remains relatively normal.
- **Grade 3 (Severe):** Marked breast enlargement with significant skin excess, often leading to a pendulous appearance. This grade may require more extensive surgical intervention due to the volume of tissue and skin involved.

This grading system aids in determining the appropriate treatment approach. In this case, the patient's classification as grade 2 gynecomastia indicated a moderate condition that warranted surgical intervention to restore a more masculine chest contour. Laboratory investigations demonstrated elevated estradiol levels and suppressed testosterone levels, confirming hormonal dysregulation. After discussing treatment options, the patient opted for surgical intervention due to psychological distress and social embarrassment caused by his condition.

Surgical intervention is preferred for the treatment of gynecomastia. For grade 2 gynecomastia, surgical excision alone can sometimes lead to crater deformity since it is impossible to remove fat from the superior and lateral parts of the chest. Liposuction alone can leave residual glandular tissue, which may cause recurrence. Therefore, a combination of liposuction and gland excision is preferred (3). The use of PAL, in this case, allowed for effective fat removal with minimized tissue trauma, leading to a smooth transition between the treated and untreated areas and resulting in a more favourable aesthetic outcome.

Aromatization and its Role in Gynecomastia:

Idiopathic gynecomastia accounts for a significant portion of cases, with estimates suggesting that it may represent around 25% to 65% of all gynecomastia cases, particularly in adolescent males. The development of gynecomastia in this context of anabolic steroid use is primarily attributed to the process of aromatization. Testosterone can be converted into estradiol, a potent form of estrogen, through the action of the aromatase enzyme. This conversion occurs in various tissues, including adipose tissue and the testes. In individuals using anabolic steroids, the increase in circulating testosterone levels can lead to a corresponding rise in estradiol due to enhanced aromatization. The resultant increase in estrogenic activity can contribute to gynecomastia and other side effects such as mood swings, fluid retention, and sexual dysfunction (1). Understanding this mechanism is crucial for effective management and prevention strategies.

Postoperatively, the patient was advised to avoid strenuous activities for at least four weeks and was scheduled for follow-up visits to monitor recovery and assess for complications. The patient reported satisfaction with the cosmetic results and improved self-esteem at the six-month follow-up.

CONCLUSION

This case illustrates the effective management of grade-2 anabolic steroid-induced gynecomastia in a young male through power-assisted liposuction and trans-nipple gland excision. The interplay between hormonal changes due to steroid use and the psychological implication of gynecomastia highlights the need for comprehensive management strategies. Awareness and education regarding the risks associated with anabolic steroid use are essential in preventing such complications.

REFERENCES

1. Beniwal M, Singh K, Singh P, et al. The Burden of Anabolic Androgenic Steroid-Induced Gynecomastia. Indian J Plast Surg. 2023;56(4):338-343. doi: 10.1055/s-0043-1771293.
2. Nuzzi LC, Cerrato FE, Erikson CR, et al. Psychosocial impact of adolescent gynecomastia: a prospective case-control study. Plast Reconstr Surg. 2013;131(4):890-896. doi: 10.1097/PRS.0b013e3182818ea8.
3. Adhikari S. Minimal Incision Technique for Gynecomastia. J Cutan Aesthet Surg. 2021;14(3):344–350. doi: 10.4103/JCAS.JCAS_96_20.

Aster
HOSPITAL
We'll Treat You Well

ASTER HOSPITAL MUHAISNAH

Your friendly neighbourhood Family Hospital



Aster
HOSPITAL
We'll Treat You Well

State-of-the-art
Medical & Surgical Care

15+
Specialities

24/7
Emergency Care

Download
my Aster

Algeria Street, Muhaisnah